



¹⁸F-FDG PET/CT in Progressive Oncocytic Carcinoma of the Parotid Gland-Case Study

Parotis Bezinin İlerleyici Onkositik Karsinomunda ¹⁸F-FDG PET/BT-Olgusu Sunumu

✉ Dushica Todorova Stefanovski¹, ✉ Aleksandar Iliev², ✉ Goran Spirov¹, ✉ Sinisha Stojanoski³, ✉ Nevena Manevska^{1,3}

¹University Institute of Positron Emission Tomography, Skopje, North Macedonia

²University Clinic for Maxillofacial Surgery Faculty of Dentistry, Ss. Cyril and Methodius University in Skopje, Skopje, North Macedonia

³Institute of Pathophysiology and Nuclear Medicine Faculty of Medicine, Ss. Cyril and Methodius University in Skopje, Skopje, North Macedonia

Abstract

Oncocytic carcinoma of the salivary glands is a very rare entity, that mainly presents in the parotid gland, either arises de-novo or is being associated with a benign oncocytoma in up to 50%. Our patient was a 60 years old male with histopathological finding of oncocytic (oxyphilic) carcinoma originating from the parotid gland with metastasis in cervical lymph nodes (postoperative stage IVA, pTNM = pT2 pN2b pMx G2 R0). On the initial preoperative ¹⁸F-fluorodeoxyglucose positron emission tomography/computed tomography (PET/CT) increased metabolic activity was seen in level IB and IIA cervical lymph nodes, suspicious for metastasis. Surgical biopsy of the parotid gland revealed oncocytic carcinoma, and then radical surgery was performed. Afterwards, patients started with immunotherapy, but because of disease progression (metastasis in the cervical, axillary, mediastinal lymph nodes and thyroid) detected on the control PET/CT scans, he was switched to chemotherapy. The patient died four years after being diagnosed with the primary cancer.

Keywords: Oncocytic carcinoma, parotid gland, ¹⁸F-FDG PET/CT

Öz

Tükürük bezlerinin onkositik karsinomu, çoğunlukla parotis bezinde ortaya çıkan, ya de novo gelişen ya da %50'ye varan oranda benign onkositom ile ilişkili olan çok nadir bir durumdur. Hastamız, parotis bezinden kaynaklanan ve servikal lenf düğümlerine metastaz yapmış onkositik (oksifilik) karsinom histopatolojik bulgusu olan 60 yaşında bir erkekti (ameliyat sonrası evre IVA, pTNM = pT2 pN2b pMx G2 R0). İlk ameliyat öncesi ¹⁸F-florodeoksiglukoz pozitron emisyon tomografisi/bilgisayarlı tomografi'de (PET/BT), metastaz şüphesi uyandıran IB ve IIA seviye servikal lenf düğümlerinde artmış metabolik aktivite görüldü. Parotis bezinin cerrahi biyopsisi onkositik karsinomu ortaya çıkardı ve ardından radikal cerrahi uygulandı. Daha sonra hastaya immünoterapi uygulandı, ancak kontrol PET/BT taramalarında saptanan hastalık ilerlemesi (servikal, aksiller, mediastinal lenf düğümlerinde ve tiroide metastaz) nedeniyle kemoterapiye geçildi. Hasta, primer kanser teşhisinden dört yıl sonra hayatını kaybetti.

Anahtar kelimeler: Onkositik karsinom, parotis bezi, ¹⁸F-FDG PET/BT

Address for Correspondence: Dushica Todorova Stefanovski, University Institute of Positron Emission Tomography, Skopje, North Macedonia

E-mail: dushica.stefanovski@uipet.mk **ORCID ID:** orcid.org/0000-0001-7629-7742

Received: 12.09.2025 **Accepted:** 15.01.2026 **Epub:** 02.04.2026

Cite this article as: Stefanovski DT, Iliev A, Spirov G, Stojanoski S, Manevska N. ¹⁸F-FDG PET/CT in progressive oncocytic carcinoma of the parotid gland-case study. Mol Imaging Radionucl Ther. [Epub Ahead of Print]



Copyright© 2026 The Author(s). Published by Galenos Publishing House on behalf of the Turkish Society of Nuclear Medicine. This is an open access article under the Creative Commons Attribution-NonCommercial-NoDerivatives 4.0 (CC BY-NC-ND) International License.

Introduction

Oncocytic carcinoma (OC) of the salivary glands is a very rare entity, that either arises de-novo or is being associated with a benign oncocytoma in up to 50% of patients (1). Oncocytoma, is commonly found in the superficial lobe of the parotid gland well-circumscribed and encapsulated. OC is characterized by large polyhedral cells with abundant granular eosinophilic cytoplasm and round to oval vesicular nuclei, sometimes with double nuclei and prominent nucleoli. Recognizing the malignant histological characteristics, such as necrosis, peri-neural spread, pleomorphism, intra-vascular invasion, and distant metastasis are crucial when differentiating between benign and malignant oncocytic tumors (2). Distant metastasis to the cervical lymph nodes, kidneys, lungs, and mediastinum are the main features of this high-grade malignant tumor (3). This type of cancer occurs mainly in the 6th decade with male predominance. Male to female ratio has been reported to be approximately 2:1 (4,5).

Case Report

Our patient was a 60 years old male with left lateral neck lymphadenopathy, who underwent fine needle aspiration biopsy, revealing classification group V. Informed written consent was obtained from the patient before the imaging. Lymph node extirpation followed and pathology report was consistent with malignant neoplasm of epithelial origin, either Hurthle cell thyroid carcinoma or parotid carcinoma. He was referred for thyroid ultrasound, that revealed no thyroid pathology and excluded primary thyroid malignancy. On the other hand, many hypoechoic lesions were detected in the left parotid gland, the largest one in the upper pole ~10 mm, as well as submandibular lymph nodes up to 12 mm, that needed further investigation.

Patient was examined by ear, nose and throat specialist, which revealed thickened mucosa in the region of the left vallecula. Further on, biopsy was performed, that showed no sign of malignancy.

On the initial ¹⁸F-fluorodeoxyglucose positron emission tomography/computed tomography (¹⁸F-FDG PET/CT) scan left cervical lymph nodes with increased metabolic activity were detected in level IB and IIA [maximum standard uptake values (SUV_{max}) = 5.2, d = 10 mm], suspicious for metastasis, few metabolically active lesions in the left parotid gland with SUV_{max} up to 4.4 that needed to be investigated and increased metabolic activity (SUV_{max} = 5.4) in the region of the left vallecula, probably due to recent biopsy. Then surgical biopsy of left parotid gland was performed and finally oral cavity (OC) was revealed as a primary.

The planned surgical procedure included eliminating all residual parotid tissue and ipsilateral cervical lymphatics. The incision encompassed most of the previous incision in the parotid region, then went in a curvilinear fashion posteriorly and inferiorly behind the sternocleidomastoid muscle (SCM), ending near the midline, below the level of the clavicle. Two flaps in the subplatysmal plane (submass in the parotid region) were developed anteriorly and posteriorly. Dissection began with identification of the main trunk of the left facial nerve. Next, the entire superficial and deep lobe of the parotid was removed with preservation of all branches of the facial nerve. Notable mass was found above the temporo-zygomatic branches of the nerve, but with a sufficient cuff of normal tissue between the mass and the nerves. Similarly, in the tail of the parotid, a palpable mass was found near the division of the marginal mandibular branch without direct contact with the nerve. The rest of the parotidectomy was done in the usual fashion without any difficulties.

Neck dissection started with identification of the Spinal accessory nerve in the posterior neck triangle above Erb's point. Then, dissection began from the Trapezius muscle and moved the fibro-fatty tissue of level V anteriorly, sparing the SAN. The lower border of the dissection was below the previous lymphadenectomy and encompassed all fibro-fatty tissue in the supraclavicular region. Dissection proceeded anteriorly above the deep layer of the deep cervical fascia until the carotid sheath was reached. Dissection then started from the anterior border of SCM, removing its fascial covering and proceeding to dissect the entire length of the jugular chain, starting from level II-b, and ending inferiorly at the level of the clavicle. Internal jugular vein was preserved, with only the linguo-facial trunk ligated and transected. Enlarged and somewhat firm nodes were identified in the jugular chain, at level II-a and level III. When the entire SCM was circumferentially freed, the specimen from the posterior neck was flipped under the muscle and connected with the anterior part of the specimen, which was removed "en block." No significant bleeding was encountered; the wound was closed in layers over two Redon drains. Recovery from general anesthesia and subsequent healing was uneventful (Figure 1).

Subsequently the histopathological finding obtained from the operative material revealed oncocytic (oxyphilic) carcinoma originating from the parotid gland with identified metastatic changes in three of total of 28 extirpated lymph nodes (stage IVA, pTNM = pT2 pN2b pMx G2 R0). Postoperative adjuvant radiotherapy was performed. Next year follow up on magnetic resonance imaging (MRI) showed no signs of local recurrence or distant metastasis.

The second PET/CT scan, performed almost two years after surgery was indicated for further investigation of enlarged axillary lymph nodes seen on the follow up CT. PET/CT findings revealed metabolically active lymph nodes in the right neck region level 3 ($SUV_{max}=4.1$), left supraclavicular region ($SUV_{max}=4.4, d\sim 11$ mm), metabolically active nodular lesion in the left pectoral muscle ($SUV_{max}=3.7, d\sim 13$ mm) and enlarged metabolically active bilateral axillary lymph nodes ($SUV_{max}=4.4, d\sim 11$ mm). All these lesions were suspicious for metastasis (Figure 2). Then bilateral cervical lymph node extirpation was done, followed by extirpation of cutaneous and subcutaneous metastases in left pectoral region. Patient started with immunotherapy pembrolizumab.

Three months later the follow up PET/CT scan revealed disease progression and new sites of metastasis in the cervical lymph nodes and new metabolically active lesion in the thyroid gland, that needed to be correlated with ultrasonography/fine-needle aspiration biopsy (Figure 3).

Ultrasound of the thyroid showed well vascularized hypoechoogenic inhomogeneous lesion in the lower part of the left thyroid lobe with microcalcifications. Fine needle aspiration biopsy that was very difficult to perform due to impaired skin due to surgery and radiation therapy (Figure 4) reported Bethesda V classification group, possible metastasis from salivary gland carcinoma.

Patient continued with immunotherapy, but the next PET/CT scan, done 6 months later, showed again disease progression with metastasis in right cervical lymph nodes, mediastinal, bilateral hilar, interpectoral, left brachial and

bilateral axillary lymph nodes (Figure 5). Subcutaneous metastasis in right pectoral and skin metastasis in left supraclavicular region were detected as well.

Patient started with chemotherapy, but considering many side effects and his low performance status, two months later agreement with the oncologist was made to cease it, continuing with symptomatic and palliative therapy only. The patient died the next year, four years after being diagnosed with this type of primary cancer.

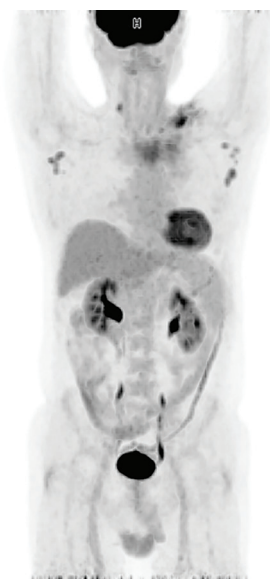

Figure 2. MIP image of the second PET/CT. Right cervical, bilateral axillary, left supraclavicular and lesion in the left pectoral muscle suspicious for metastasis. MIP: Maximum intensity projection, PET/CT: Positron emission tomography/computed tomography

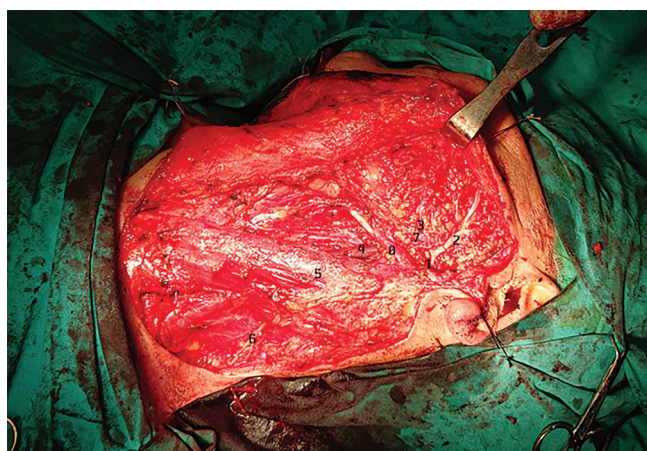


Figure 1. Operative field prior closure (1) Main trunk of left facial nerve, (2) Temporo-zygomatic branch, (3) Cervico-mandibular branch, (4) Internal jugular vein, (5) Sternocleidomastoid muscle, (6) Accessory nerve, (7) Retromandibular vein, (8) Stylohyoid and posterior venter of digastric muscle

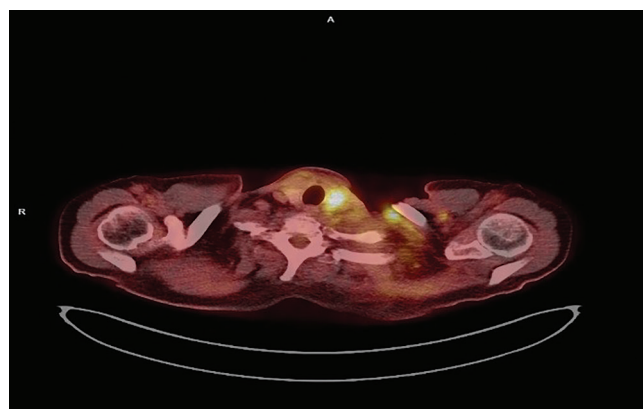


Figure 3. ^{18}F -FDG PET/CT fusion image of thyroid lesion. ^{18}F -FDG PET/CT: ^{18}F -fluorodeoxyglucose positron emission tomography/computed tomography

Discussion

OC together with oncocytosis and oncocytoma present very exceptional oncocytic neoplasms of the salivary gland. Very few cases have been reported in the literature so far. It accounts for 11% of all oncocytic salivary gland neoplasms,

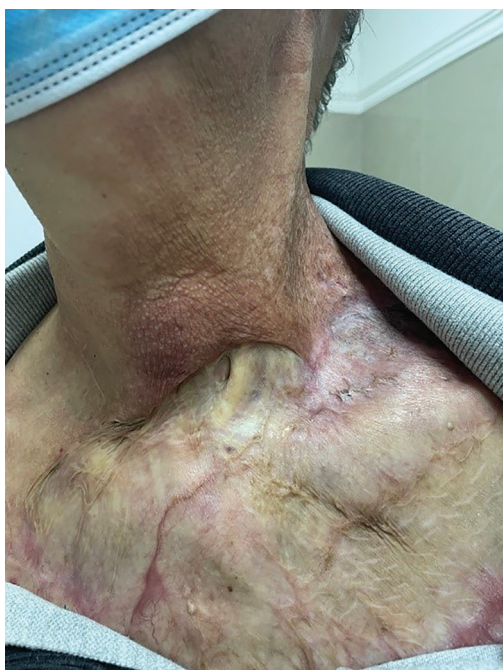

Figure 4. Skin lesions after surgery and radiation therapy

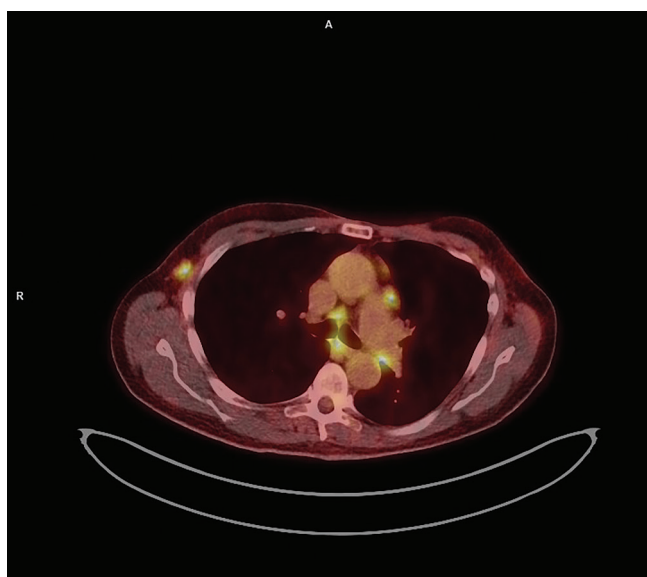


Figure 5. ^{18}F -FDG PET/CT fusion image of lymph node metastasis
Mediastinal and right axillar metastasis
 ^{18}F -FDG PET/CT: ^{18}F -fluorodeoxyglucose positron emission tomography/computed tomography

0.5% of all epithelial salivary gland malignancies and 0.18% of all epithelial salivary gland tumours (6). In the study of Capone et al. (7) twenty-one parotid oncocytic neoplasms were identified in the period 1984-2000, with OC being the rarest (9.5%), then oncocytosis (28.5%) and the most frequent was oncocytoma (62%).

Since similarities between oncocytic neoplasms do exist, and fine needle aspiration biopsy can not confirm the diagnosis, consequently the pathology analysis remains the gold standard. Nonetheless, features such as rapid enlargement, facial nerve involvement, or fixation to adjacent structures should be taken into consideration for prompt suspicion for malignancy (8).

The surgical management of parotid oncocytic carcinoma, usually involves a total or partial parotidectomy. This is preferred due to the tumor's aggressive nature and potential for recurrence. Enucleations are usually followed by a recurrence and are not considered as optimal treatment choices, especially given the fact that every subsequent parotid surgery is levels of magnitude more and more difficult and technically complicated. Wherever possible, the facial nerve is dissected and preserved, though extended resections may be necessary if nearby tissues are affected (9).

Neck dissection may also be included in the surgical plan when lymph node involvement is present. The general plan needs to be aggressive since all recurrences have a poor outcome (10).

Cinar et al. (11) reported 48-year-old woman whose disease had metastasized to regional lymph nodes, was treated by radical parotidectomy, with sacrifice of the facial nerve, and radical neck dissection. At the 3-year follow-up, she remained free of disease.

A case of a 70-year-old man was reported by Wan Ahmad Kammal et al. (12) that had a history of left parotid swelling over the past 10 years. A parotid tumor 3x3 cm was identified and grade 4 facial nerve palsy. He was treated with a left total parotidectomy, selective neck dissection and adjuvant radiotherapy with a total dose of 66 Gy within six weeks.

New biomarker research has identified promising prognostic indicators, such as p53 mutations, Ki-67 proliferation index, and mitochondrial DNA mutations. These biomarkers can help predict the tumor's behavior, guiding more tailored decisions about adjuvant radiotherapy and other postoperative treatments. Immunohistochemical markers, including cytokeratins and oncocytic markers, have further refined diagnostic accuracy, enabling more effective surgical planning (13).

Conclusion

According to the Management of Salivary Gland Malignancy in the guideline, ¹⁸F-FDG PET/CT has no role when used for the initial evaluation of a parotid mass, but may more accurately predict the extent of nodal and distant metastatic disease in high-grade tumors and identify locoregionally recurrent and metastatic disease. Post-treatment baseline imaging with PET/CT should be obtained 3 months after completion of all treatment (14).

Westergaard-Nielsen et al. (15) found that PET/CT diagnosed cervical lymph node metastases in four patients where MRI did not. These patients were still treated with curative intent, but the surgical procedure with neck dissection was changed based on PET/CT report. Overall, PET/CT changed treatment in three patients with distant metastases and four patients with regional metastases, representing 21% (7/33) of the patients with salivary gland carcinoma.

The prognosis of OC in salivary gland depends primarily on the tumor grade, stage and completeness of resection. The 5-year survival rate for low-grade types goes over 80%-90% and these tumors have favorable outcomes. On the other hand, high-grade carcinoma, show lower 5-year survival ranging between 40% and 60%, due to higher risks of local recurrence, perineural invasion, and metastasis and thus have poorer prognosis (8). Patients with malignant oncocytoma appear to have good short-term survival, but poor long-term survival. The average survival period has been estimated at 3.8 years with metastasizing tumors (3).

Ethics

Informed Consent: Informed written consent was obtained from the patient before the imaging.

Footnotes

Authorship Contributions

Surgical and Medical Practices: D.T.S., A.I., G.S., Concept: S.S., N.M., Design: S.S., N.M., Data Collection or Processing: D.T.S., N.M., Analysis or Interpretation: G.S., Literature Search: D.T.S., N.M., Writing: D.T.S., A.I.

Conflict of Interest: No conflicts of interest were declared by the authors.

Financial Disclosure: The authors declare that this study has received no financial support.

References

1. Lee WY, Chang SL. Fine needle aspiration cytology of oncocytic carcinoma of the submandibular gland with pre-existing oncocytoma: a case report. *Cytopathology*. 2010;21:339-341.
2. Parmar R, Kalaria AN, Patel KA. Oncocytic lesions of salivary glands: morphological, immunohistochemical, and molecular findings. *Cureus*. 2024;16:e59328.
3. Gallego L, García-Consuegra L, Fuente E, Calvo N, Junquera L. Oncocytic carcinoma of the parotid gland with late cervical lymph node metastases: a case report. *J Med Case Rep*. 2011;5:11.
4. Ellis GL, Auclair PL. Tumors of the salivary glands. AFIP Atlas of Tumor Pathology, 4th Series, Fascicle 9. Silver Spring, MD: ARP Press; 2008.
5. Nakada M, Nishizaki K, Akagi H, Masuda Y, Yoshino T. Oncocytic carcinoma of the submandibular gland: a case report and literature review. *J Oral Pathol Med*. 1998;27:225-228.
6. Lee TH, Lin YS, Lee WY, Wu TC, Chang SL. Malignant transformation of a benign oncocytoma of the submandibular gland: a case report. *Kaohsiung J Med Sci*. 2010;26:327-332.
7. Capone RB, Ha PK, Westra WH, Pilkington TM, Sciubba JJ, Koch WM, Cummings CW. Oncocytic neoplasms of the parotid gland: a 16-year institutional review. *Otolaryngol Head Neck Surg*. 2002;126:657-662.
8. Azouaghe Y, Haddadi Z, Zohir M, Banana Y, Sbai AA, Benfadil D, Lachkar A, Idrissi FEAE. Oncocytic carcinoma of the parotid gland: a rare malignancy with diagnostic and therapeutic challenges. *Radiol Case Rep*. 2025;20:5420-5426.
9. Locati LD, Ferrarotto R, Licitra L, Benazzo M, Preda L, Farina D, Gatta G, Lombardi D, Nicolai P, Vander Poorten V, Chua MLK, Vischioni B, Sanguineti G, Morbini P, Fonseca I, Sozzi D, Merlotti A, Orlandi E. Current management and future challenges in salivary glands cancer. *Front Oncol*. 2023;13:1264287.
10. Westergaard-Nielsen M, Godballe C, Andersen LJ, Primdahl H, Kristensen CA, Andersen E, Bjørndal K. Oncocytic carcinoma of the salivary glands: a Danish national study. *Auris Nasus Larynx*. 2018;45:825-830.
11. Cinar U, Vural C, Basak T, Turgut S. Oncocytic carcinoma of the parotid gland: report of a new case. *Ear Nose Throat J*. 2003;82:699-701.
12. Wan Ahmad Kammal WS, Azman M, Salleh AA, Md Pauzi SH, Abd Shukur N. Parotid gland oncocytic carcinoma: a rare entity in head and neck region. *Malays J Pathol*. 2020;42:283-286.
13. Alshammari A, Aljufairi E, Alsayed A. Oncocytic mucoepidermoid carcinoma of the parotid gland: case report. *J Surg Case Rep*. 2022;2022:rjac039.
14. Geiger JL, Ismaila N, Beadle B, Caudell JJ, Chau N, Deschler D, Glastonbury C, Kaufman M, Lamarre E, Lau HY, Licitra L, Moore MG, Rodriguez C, Roshal A, Seethala R, Swiecicki P, Ha P. Management of salivary gland malignancy: ASCO guideline. *J Clin Oncol*. 2021;39:1909-1941.
15. Westergaard-Nielsen M, Rohde M, Godballe C, Eriksen JG, Larsen SR, Gerke O, Nguyen N, Nielsen MK, Nielsen AL, Thomassen A, Asmussen JT, Diaz A, Høilund-Carlsen PF, Bjørndal K. Up-front F18-FDG PET/CT in suspected salivary gland carcinoma. *Ann Nucl Med*. 2019;33:554-563.