



Hydatid Cyst Infection of the Tibia Mimicking Chondrosarcoma on ¹⁸F-FDG PET/CT Scan

¹⁸F-FDG PET/BT Taramasında Kondrosarkomu Taklit Eden Tibial Kist Hidatik Enfeksiyonu

✉ Furkan Avcı¹, ✉ Batuhan Kocabeyođlu¹, ✉ İpek Tamsel², ✉ Hüseyin Kaya³, ✉ Başak Dođanavşargil⁴, ✉ Zehra Özcan¹

¹Ege University Faculty of Medicine, Department of Nuclear Medicine, İzmir, Türkiye

²Ege University Faculty of Medicine, Department of Radiology, İzmir, Türkiye

³Ege University Faculty of Medicine, Department of Orthopedics, İzmir, Türkiye

⁴Ege University Faculty of Medicine, Department of Pathology, İzmir, Türkiye

Abstract

A hydatid cyst is a zoonotic infection caused by *Echinococcus granulosus*. The liver and lungs are the most affected organs. Although rare, osseous involvement by hydatid cyst disease can occur because the rigid bone trabeculae prevent formation of the characteristic adventitia. While fluorodeoxyglucose (FDG) positron emission tomography (PET) findings in hepatic and pulmonary hydatid cysts are well described, this case, to the best of our knowledge, represents the first report of bone hydatid disease located in an extremity evaluated by ¹⁸F-FDG PET/computed tomography.

Keywords: Hydatid cyst, bone diseases, infection, ¹⁸F-FDG PET/CT

Öz

Hidatik kist, *Echinococcus granulosus* tarafından oluşturulan zoonotik bir enfeksiyondur ve en sık karaciđer ile akciđerleri tutar. Nadir olmakla birlikte, kemik trabeküllerinin sert yapısı karakteristik adventisya oluşumunu engellediđinden, hidatik kist hastalığı kemik dokusunu da etkileyebilir. Karaciđer ve akciđer hidatik kistlerinde florodeoksiglukoz (FDG) pozitron emisyon tomografi (PET) bulguları iyi tanımlanmış olsa da, bildiđimiz kadıyla bu olgu, ekstremite yerleşimli kemik hidatik hastalığının ¹⁸F-FDG PET/bilgisayarlı tomografi ile değerlendirildiđi ilk olgu olma özelliđini taşımaktadır.

Anahtar Kelimeler: Kist hidatik, kemik hastalıkları, enfeksiyon, ¹⁸F-FDG PET/BT

Address for Correspondence: Furkan Avcı, Ege University Faculty of Medicine, Department of Nuclear Medicine, İzmir, Türkiye

E-mail: furkan.avci@ege.edu.tr **ORCID ID:** orcid.org/0009-0002-2392-2190

Received: 16.07.2025 **Accepted:** 25.11.2025 **Epub:** 19.12.2025 **Publication Date:** 04.06.2026

Cite this article as: Avcı F, Kocabeyođlu B, Tamsel İ, Kaya H, Dođanavşargil B, Özcan Z. Hydatid cyst infection of the tibia mimicking chondrosarcoma on ¹⁸F-FDG PET/CT scan. Mol Imaging Radionucl Ther. 2026;35(2):127-130.



Copyright© 2026 The Author(s). Published by Galenos Publishing House on behalf of the Turkish Society of Nuclear Medicine. This is an open access article under the Creative Commons Attribution-NonCommercial-NoDerivatives 4.0 (CC BY-NC-ND) International License.

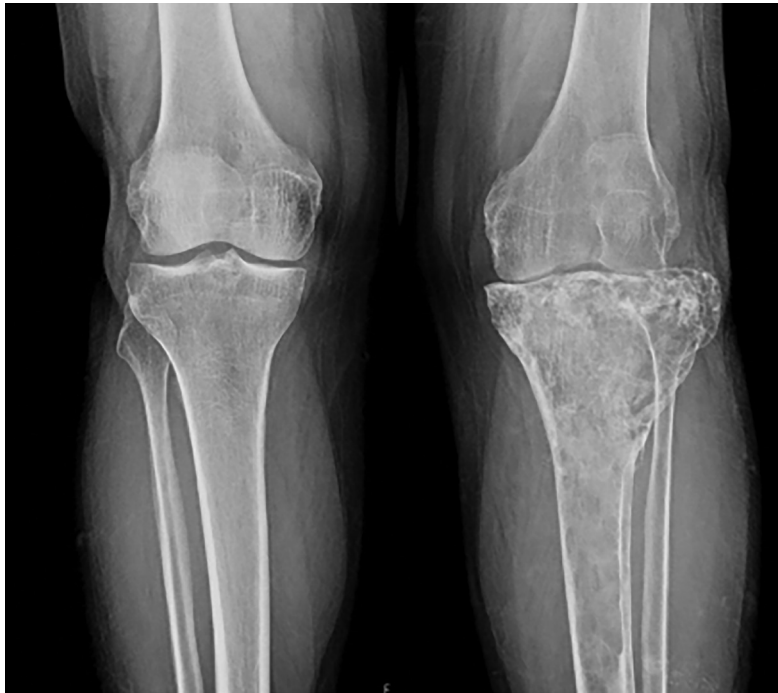

Figure 1. A 54-year-old male patient presented with progressively worsening pain and swelling localized to the left knee. Initial radiological evaluation using anteroposterior X-ray imaging demonstrated extensive lytic-destructive lesions predominantly involving the proximal metaphysis of the left tibia. Radiographic features included marked trabecular disruption, cortical thinning, and expansion of the medullary cavity. Given these aggressive radiological findings, a primary bone malignancy, particularly chondrosarcoma, was considered a preliminary diagnosis.

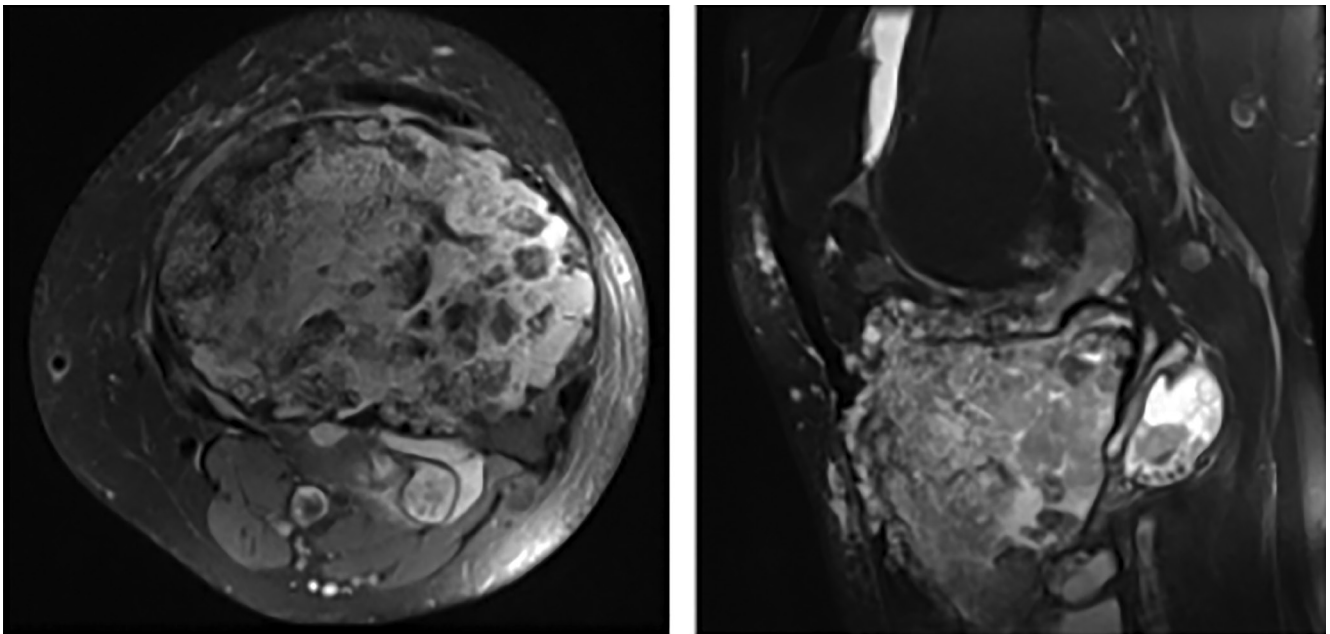


Figure 2. Subsequent magnetic resonance imaging (MRI) was conducted to further characterize the lesion. Axial (A) and sagittal (B) T2-weighted MRI sequences revealed a large, cystic lesion localized at the epiphyseal-metaphyseal junction of the proximal tibia. The lesion exhibited characteristic internal septations, focal chondroid-like calcifications, and prominent soft-tissue infiltration extending beyond the bone marrow cavity into surrounding musculature and adipose tissue. These radiological findings strongly supported the initial clinical suspicion of chondrosarcoma, necessitating further staging investigations.

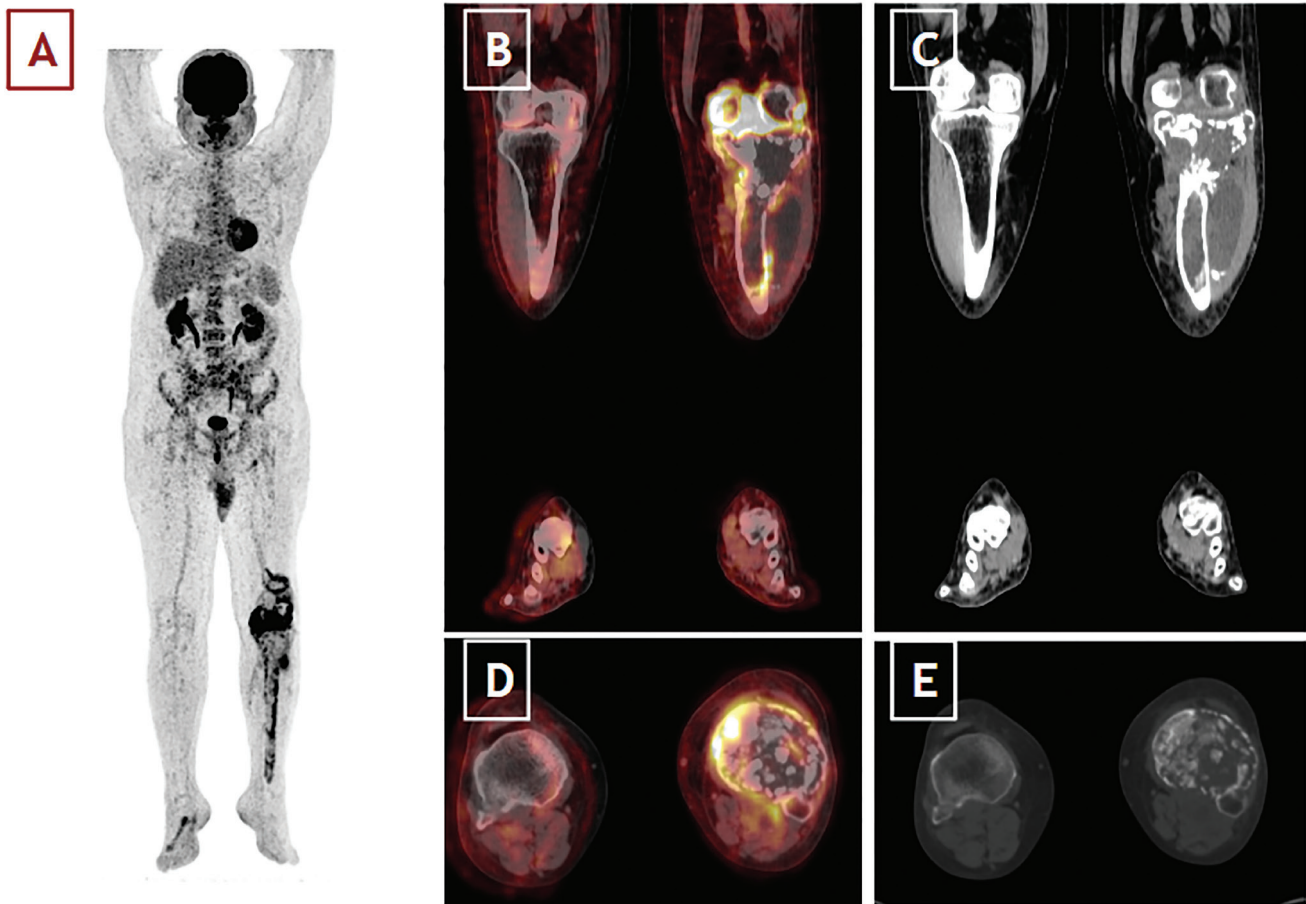


Figure 3. To assess systemic involvement and metastatic potential, an ^{18}F -fluorodeoxyglucose positron emission tomography/computed tomography (^{18}F -FDG PET/CT), scan was performed. Maximum-intensity projection imaging (A) identified intensely hypermetabolic foci (maximum standard uptake values: 27.3) in the proximal left tibia and distal femur. On coronal (B, C) and axial (D, E) fused PET/CT images, the lesions demonstrated marked cortical destruction with irregular margins and peripheral, heterogeneous FDG uptake. Within the bone marrow, cystic and lytic areas showed relatively low or absent tracer accumulation, suggestive of necrotic or fluid-filled components, whereas the surrounding soft-tissue extensions were markedly hypermetabolic and contained partially calcified densities. Mild periosteal reaction and adjacent soft-tissue edema were also evident, indicating biologic aggressiveness. Additionally, mild FDG uptake was noted in the left inguinal lymph nodes and was interpreted as reactive rather than metastatic. Because of persistent suspicion of malignancy on imaging, a tru-cut biopsy was performed. Histopathological analysis unexpectedly identified a solitary osseous hydatid cyst (caused by *Echinococcus granulosus*). No additional disease foci were detected upon further systemic evaluation with abdominal and thoracic CT imaging. The patient received antiparasitic therapy with albendazole, followed by successful surgical excision of the lesion. Although rare, hydatid cyst disease can also involve osseous structures because the rigidity of trabecular bone prevents formation of the characteristic adventitia 1-5. While FDG PET findings in hepatic 6 and pulmonary 7 hydatid cysts are well described, this case highlights the importance of considering osseous hydatid disease in the differential diagnosis of aggressive bone lesions, particularly in endemic regions.

Ethics

Informed Consent: Informed consent was obtained from the patient for publication of this case and accompanying images.

Footnotes

Authorship Contributions

Surgical and Medical Practices: H.K., B.D., Design: B.K., Data Collection or Processing: F.A., İ.T., Analysis or Interpretation: İ.T., Literature Search: F.A., Z.Ö., Writing: F.A., Z.Ö.

Conflict of Interest: No conflicts of interest were declared by the authors.

Financial Disclosure: The authors declare that this study has received no financial support.

References

1. Takenaka J, Hirata K, Watanabe S, Takahata M, Kudo K. Bone echinococcosis mimicking malignancy on FDG PET. *Clin Nucl Med.* 2023;48:e523-e525. Epub 2023 Sep 18.
2. Arkun R, Mete BD. Musculoskeletal hydatid disease. *Semin Musculoskelet Radiol.* 2011;15:527-540. Epub 2011 Nov 11.
3. Jamshidi K, Zandrahimi F, Haji Agha Bozorgi M, Mirkamali SF, Esmaeli Dahaj A, Mirzaei A. Non-spinal hydatid disease of bone: a series of nine cases. *Arch Bone Jt Surg.* 2022;10:447-452.
4. Kalinova K, Proichev V, Stefanova P, Tokmakova K, Poriazova E. Hydatid bone disease: a case report and review of the literature. *J Orthop Surg (Hong Kong).* 2005;13:323-325.
5. Manenti G, Censi M, Pizzicannella G, Pucci N, Pitocchi F, Calcagni A, Amico A, Collura A, Ryan CP. Vertebral hydatid cyst infection. A case report. *Radiol Case Rep.* 2020;15:523-527.
6. Alghofaily KA, Saeedan MB, Aljohani IM, Alrasheed M, McWilliams S, Aldosary A, Neimatallah M. Hepatic hydatid disease complications: review of imaging findings and clinical implications. *Abdom Radiol (NY).* 2017;42:199-210.
7. Aydin Y, Ulas AB, Ahmed AG, Eroglu A. Pulmonary hydatid cyst in children and adults: diagnosis and management. *Eurasian J Med.* 2022;54(Suppl1):133-140.