



# Testicular Incidentaloma on $^{18}\text{F}$ -choline PET/CT in a Patient with Prostatic Adenocarcinoma

## Prostatik Adenokarsinomlu Bir Hastada $^{18}\text{F}$ -kolin PET/BT ile Saptanan Testiküler İnsidentaloma

Chaymae Bensaid, Salah Oueriagli Nabih, Meryem Aboussabr, Omar Ait Sahel, Yassir Benameur, Abderrahim Doudouh

Mohammed V Military Training Hospital, Clinic of Nuclear Medicine, Rabat, Morocco

### Abstract

Prostatic adenocarcinoma is characterized by elevated phosphatidylcholine metabolism.  $^{18}\text{F}$ -choline positron emission tomography/computed tomography (PET/CT) is widely used for patients with biochemical recurrence and a prostate-specific antigen threshold above 2 ng/mL. We report a case of a patient with high-risk prostatic adenocarcinoma undergoing  $^{18}\text{F}$ -choline PET/CT for biochemical recurrence. In addition to hypermetabolic abdominal lymph nodes, an unexpected right testicular hypermetabolism was observed. Such findings on  $^{18}\text{F}$ -choline PET/CT may suggest a primary tumor or testicular metastasis of prostate cancer. Bilateral orchiectomy revealed a vitelline tumor associated with known primary prostatic cancer. The incidental discovery of a testicular vitelline tumor during prostate cancer imaging is rare, highlighting the importance of thorough diagnostics. This case underscores the need for comprehensive care in managing complex and atypical cancer cases, emphasizing the potential for unrelated tumor discoveries during diagnostic workup. Further research is essential for a better understanding of these rare co-occurring cancers and their treatment implications.

**Keywords:**  $^{18}\text{F}$ -choline positron emission tomography/computed tomography, yolk tumor, prostatic adenocarcinoma

### Öz

Prostatik adenokarsinom, yüksek fosfatidilkolin metabolizması ile karakterizedir.  $^{18}\text{F}$ -kolin pozitron emisyon tomografisi/bilgisayarlı tomografi (PET/BT), biyokimyasal nüks olan ve prostat spesifik antijen düzeyi 2 ng/mL'nin üzerinde olan hastalarda yaygın olarak kullanılmaktadır. Biyokimyasal nüks nedeniyle  $^{18}\text{F}$ -kolin PET/BT uygulanan yüksek riskli prostat adenokarsinomlu bir hastayı bildiriyoruz. Hipermetabolik karın lenf nodlarına ek olarak sağ testiste beklenmedik bir hipermetabolizma da gözlemlendi.  $^{18}\text{F}$ -kolin PET/BT'deki bu tür bulgular, bir primer tümörü veya prostat kanserinin testiküler metastazını düşündürülebilir. Bilateral orşiektomi, bilinen primer prostat kanseri ile ilişkili bir vitellin tümörü ortaya çıkardı. Prostat kanseri görüntülemesi sırasında testiküler vitellin tümörünün tesadüfen keşfedilmesi nadirdir, bu da teşhise yönelik kapsamlı araştırmanın önemini vurgulamaktadır. Bu olgu, karmaşık ve atipik kanserli olgularının yönetilmesinde kapsamlı bakım ihtiyacının altını çizmekte ve teşhis için yapılan araştırmalar sırasında ilgisiz tümör keşiflerinin potansiyelini vurgulamaktadır. Nadiren birlikte ortaya çıkan bu kanserlerin ve bunların tedavilerinin yol açacağı etkilerin daha iyi anlaşılması için daha fazla araştırma yapılması gerekmektedir.

**Anahtar kelimeler:**  $^{18}\text{F}$ -kolin pozitron emisyon tomografisi/bilgisayarlı tomografi, yolk tümörü, prostat adenokarsinomu

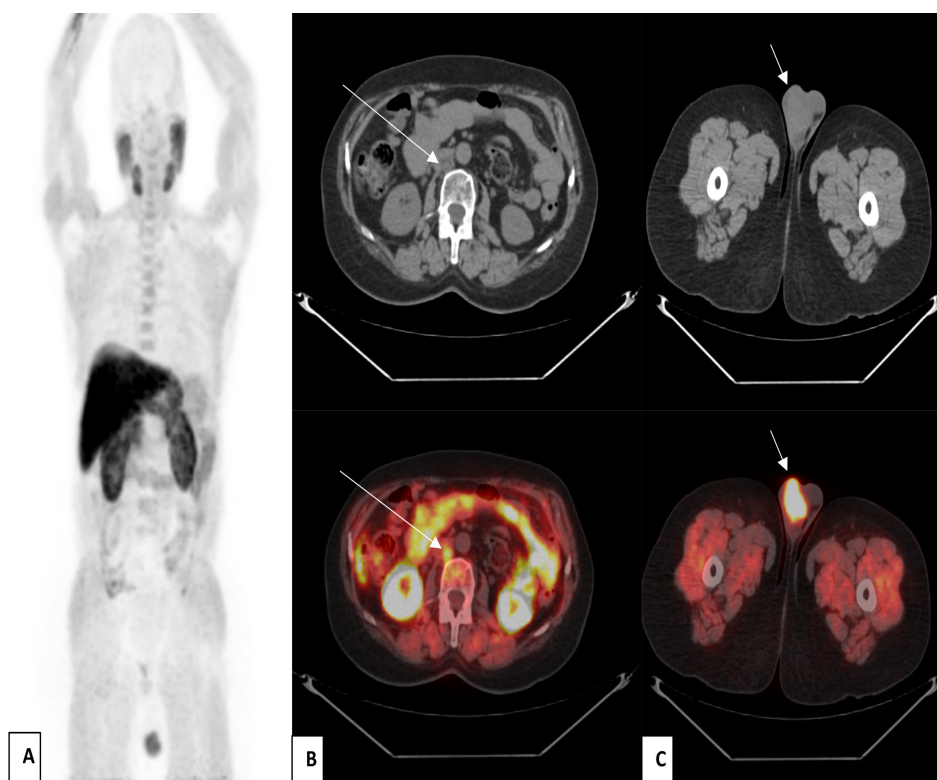
**Address for Correspondence:** Chaymae Bensaid MD, Mohammed V Military Teaching Hospital, Clinic of Nuclear Medicine, Rabat, Morocco

**Phone:** +212623511726 **E-mail:** chamabensaid@gmail.com ORCID ID: orcid.org/0009-0002-2164-0982

**Received:** 17.01.2024 **Accepted:** 12.02.2024 **Epub:** 20.02.2024



Copyright© 2024 The Author. Published by Galenos Publishing House on behalf of the Turkish Society of Nuclear Medicine. This is an open access article under the Creative Commons Attribution-NonCommercial-NoDerivatives 4.0 (CC BY-NC-ND) International License.

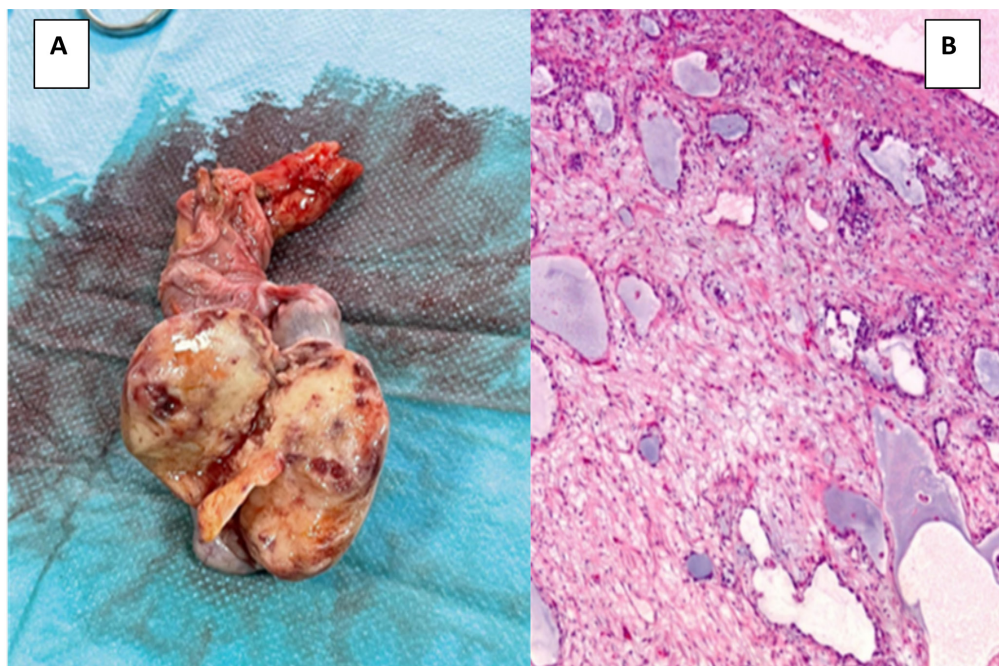


**Figure 1.** A 69-year-old patient was followed up since 2019 for high-risk prostatic adenocarcinoma Gleason 9 (4+5), which was treated by external radiotherapy and subsequently introduced to novel hormonotherapy. The evolution was unremarkable for 2 years. The patient was lost to follow-up for 1 year and returned in 2023 with a prostate-specific antigen level of 7.3 ng/mL.  $^{18}\text{F}$ -choline positron emission tomography/computed tomography (PET/CT) scan was ordered as part of recurrence assessment, which showed the physiological and pathological distribution of the radiopharmaceutical ( $^{18}\text{F}$ -choline) (maximum intensity projection; A) and revealed the presence of a suspicious pathological hypermetabolic lymphadenopathy interaortic cavity [the maximum standardized uptake value ( $\text{SUV}_{\text{max}}$ ) was 4.4], suggesting of lymph node recurrence (CT and fusion images in axial sections; arrow; B), besides the absence of suspicious hypermetabolism in the prostatic lodge.

In the CT and fusion images in axial sections (arrow; C), we also noted the presence of a suspicious right testicular nodule measuring 43x30 mm with an intense hypermetabolism ( $\text{SUV}_{\text{max}}=8.8$ ). Our findings suggest two diagnoses: primary cancer or rare testicular metastasis of prostate cancer.

Rare testicular hypermetabolism requires prompt reporting by the nuclear medicine physician, prompting a follow-up testicular ultrasound, especially if CT scan shows suspicious abnormalities. Testicular ultrasonography showed two contiguous, well-limited, heterogeneous tissue nodules taking color Doppler and containing microcalcifications, measuring 23x27 mm and 19x20 mm respectively.

Few cases of testicular involvement in prostate cancer have been reported in the literature using  $^{18}\text{F}$ -choline PET/CT. Identifying a testicular lesion in a familial neoplastic context, particularly in prostatic cases, requires careful investigation and histological confirmation to distinguish metastatic from primary origin (1).



**Figure 2.** The patient underwent bilateral orchietomy (bilateral orchietomy surgical specimen; A), and the morphological and immunohistochemical profile was consistent with a testicular primary cancer (pathological section of the poorly differentiated carcinomatous testicular process; B), in particular a yolk tumor.  $^{18}\text{F}$ -choline PET/CT allowed us to discover, in addition to lymph node recurrence, a rare and asymptomatic testicular primary cancer, which was accessible and resectable. Orchietomy seemed essential in the absence of histological evidence that could confirm the diagnosis. The yolk tumor discovered fortuitously is an uncommon histological variant of non-seminomatous germ cell tumors in adults (2), and its binding to  $^{18}\text{F}$ -choline remains non-specific and poorly defined. Calabrò et al. (3) reported also a case of incidental finding of testicular seminoma by  $^{18}\text{F}$ -choline PET/CT in a prostate cancer patient. Also, Cegla et al. (4) reported that incidental detection of a second primary cancer in prostate cancer patients using  $^{18}\text{F}$ -choline PET/CT is not very common and that lung cancer and hematologic malignancies are most frequently detected at 50% and 19% of cases, respectively, and less often a testicular cancer.

Moreover, the presence of this unusual testicular hypermetabolism poses challenges in terms of differential diagnosis, especially testicular secondary involvement, which is uncommon (2-3% prevalence) and is typically discovered during autopsy or orchidectomy. Prostate cancer nearly constitutes half of all testicular metastases, with suggested dissemination through different ducts or vascular networks, emphasizing an unconventional metastatic pathway. Foret et al. (5) reported a rare instance of isolated testicular recurrence of prostatic adenocarcinoma identified via  $^{18}\text{F}$ -fluorocholine PET/CT. Furthermore, there are no studies in the literature addressing the various diagnoses to consider in the presence of this testicular hypermetabolism, particularly benign testicular pathologies unrelated to neoplastic contexts.

This case underscores the pivotal role of  $^{18}\text{F}$ -choline PET/CT in the management of prostatic neoplasia, revealing a rare primary testicular cancer. It highlights the need for additional scientific studies and emphasizes the importance of systematic pathological examination post-surgical castration for improved differential diagnosis and enhanced control of prostatic neoplasia, especially after addressing lymph node recurrence. In addition, the discovery of a testicular vitelline tumor during  $^{18}\text{F}$ -choline investigation for prostate cancer emphasizes the significance of thorough imaging and testing. It stresses the requirement for comprehensive, multidisciplinary care in addressing complex cases, urging further research to understand the implications and potential treatment strategies for these uncommon concurrent cancers.

## Ethics

**Informed Consent:** Informed consents of the patient was obtained.

## Authorship Contributions

Concept: C.B., S.O.N., M.A., O.A.S., Y.B., A.D., Design: C.B., S.O.N., O.A.S., Y.B., A.D., Data Collection or Processing: C.B., Analysis or Interpretation: C.B., S.O.N., A.D., Literature Search: C.B., M.A., Writing: C.B.

**Conflict of Interest:** No conflicts of interest were declared by the authors.

**Financial Disclosure:** The authors declare that this study has received no financial support.

## References

1. Bauduceau O, Vedrine L, Chargari C, Ceccaldi B, Le Moulec S, Houlgatte A. Métastase testiculaire d'un adénocarcinome prostatique: à propos d'un cas [Testicular metastasis of prostatic adenocarcinoma: a case report]. *Prog Urol.* 2007;17:251-252. French.
2. Zizi M, Ziouziou I, El Yacoubi S, Khmou M, Jahid A, Mahassini N, Karmouni T, El Khader K, Koutani A, Andaloussi AI. Tumeur du sac vitellin du testicule au stade IIIc métastatique : à propos d'un cas. *Can Urol Assoc J.* 2014;8:E663-E665. French.
3. Calabrò A, Bosio G, Drera E, Giubbini R, Bertagna F. Incidental Finding of Testicular Seminoma by 18F-Choline PET/CT in a Prostate Cancer Patient. *Clin Nucl Med.* 2022;47:e249-e251.
4. Cegla P, Scibisz-Dziedzic K, Witkowska K, Kubiak A, Wierzoslawska E, Kycler W, Chrapko B, Czepczyński R. Detection of a second primary cancer in a 18F-fluorocholine PET/CT - multicentre retrospective analysis on a group of 1345 prostate cancer patients. *Nucl Med Rev Cent East Eur.* 2022;25:25-30.
5. Foret T, Dimier JP, Skanjeti A, Dhomps A, Tordo J. Récidive testiculaire isolée d'un adénocarcinome prostatique révélée par TEP/TDM 18F-fluorocholine [Solitary testicular metastasis from prostate adenocarcinoma revealed by <sup>18</sup>F-fluorocholine PET/CT]. *Médecine Nucléaire.* 2020;44:76-78.