



# Can Pantoprazole be Used for Premedication in Meckel Scintigraphy?

## Pantoprazol Meckel Sintigrafisinde Premedikasyon Amacıyla Kullanılabilir mi?

© Aziz Gültekin, © Tark Şengöz, © Samiye Demirezen, © Doğangün Yüksel

Pamukkale University Faculty of Medicine, Department of Nuclear Medicine, Denizli, Türkiye

### Abstract

**Objectives:** Meckel scintigraphy is used to diagnose Meckel's diverticulum. Previously, premedication with ranitidine was the most frequently used method to increase the accuracy of scintigraphy. However, ranitidine can no longer be used because it is banned by the Food and Drug Administration. The aim of this study was to investigate the usability of pantoprazole as a premedication instead of ranitidine in Meckel scintigraphy.

**Methods:** Twelve New Zealand rabbits were used in this experimental study. Rabbits were divided into two groups: pantoprazole and control. Six rabbits were premedicated with pantoprazole for three days. Meckel scintigraphy was performed on all rabbits. Counts were made and compared by drawing regions of interest from the stomach walls.

**Results:** According to the findings of this experimental study, pantoprazole significantly increased Tc-99m-pertechnetate uptake in the stomach of rabbits on both visual and quantitative evaluation.

**Conclusion:** Pantoprazole increases the gastric wall uptake of Tc-99m-pertechnetate in rabbits and is a potential drug for premedication in Meckel scintigraphy.

**Keywords:** Meckel's diverticulum, Meckel scintigraphy, preclinical imaging, pantoprazole, premedication for Meckel scan

### Öz

**Amaç:** Meckel divertikülü tanısında Meckel sintigrafisi kullanılmaktadır. Önceleri sintigrafi doğruluğunu artırmak amacıyla ranitidin ile premedikasyon en sık kullanılan yöntemdi. Ancak Gıda ve İlaç Dairesi tarafından yasaklandığı için artık kullanılamamaktadır. Bu çalışmanın amacı Meckel sintigrafisinde ranitidin yerine pantoprazolün premedikasyon amacıyla kullanılabilirliğini araştırmaktır.

**Yöntem:** Bu deneysel çalışmada 12 Yeni Zelanda tavşanı kullanıldı. Tavşanlar pantoprazol ve kontrol grubu olmak üzere iki gruba ayrıldı. Altı tavşana üç gün boyunca pantoprazol ile premedikasyon uygulandı. Hem kontrol grubu hem de pantoprazole grubu tüm tavşanlara Meckel sintigrafisi yapıldı. Mide duvarından ilgi alanları çizilerek sayımlar yapıldı ve karşılaştırıldı.

**Bulgular:** Bu deneysel çalışmadan elde ettiğimiz bulgulara göre pantoprazol, görsel ve kantitatif değerlendirme sonucunda tavşan midesinde Tc-99m-pertechnetat alımını önemli ölçüde artırmaktadır.

**Sonuç:** Pantoprazol tavşanlarda Tc-99m-pertechnetatın mide duvarına alımını artırır ve Meckel sintigrafisinde premedikasyon için kullanılacak potansiyel bir ilaçtır.

**Anahtar kelimeler:** Meckel divertikülü, Meckel sintigrafisi, klinik öncesi görüntüleme, pantoprazol, Meckel sintigrafisinde premedikasyon

**Address for Correspondence:** Aziz Gültekin Assoc. Prof., Pamukkale University Faculty of Medicine, Department of Nuclear Medicine, Denizli, Türkiye

**Phone:** +90 258 296 53 06 **E-mail:** agulteakin@pau.edu.tr ORCID ID: orcid.org/0000-0002-0311-8077

**Received:** 15.12.2023 **Accepted:** 03.03.2024 **Epub:** 04.04.2024



Copyright© 2024 The Author. Published by Galenos Publishing House on behalf of the Turkish Society of Nuclear Medicine.  
This is an open access article under the Creative Commons Attribution-NonCommercial-NoDerivatives 4.0 (CC BY-NC-ND) International License.

## Introduction

Only 30-60% of Meckel's diverticulum contains ectopic gastric mucosa. Meckel's diverticulum, which contains ectopic gastric mucosa, can be detected by Meckel scintigraphy. Tc-99m-pertechnetate is used as a radiopharmaceutical in Meckel scintigraphy (1,2,3). Tc-99m-pertechnetate is taken up by the cells of the gastric mucosa, which produce mucin and are then secreted into the intestine. Meckel scintigraphy with Tc-99m-pertechnetate is used to identify ectopic gastric mucosa in Meckel's diverticulum (4,5). This examination is widely used in diagnosis and has a wide accuracy range (6,7). Various premedication methods have been used to increase the accuracy of Meckel scintigraphy. The most commonly used preparations for this purpose are H<sub>2</sub> receptor blockers (famotidine, cimetidine, and ranitidine), pentagastrin, and glucagon. Pentagastrin and glucagon are not suitable for use because of side effects (8,9,10,11). Ranitidine was the most frequently used preparation previously. The use of ranitidine has been banned by the Food and Drug Administration (FDA) because of its N-nitrosodimethylamine (NDMA) content. NDMA has been proven to cause lung, liver, and bladder cancer in animals (12,13). For the same reason, ranitidine preparations have been withdrawn from medical markets worldwide.

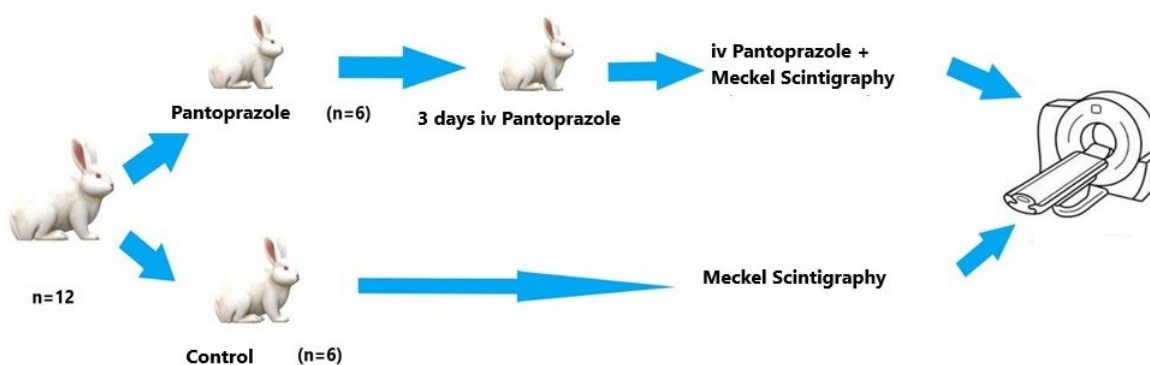
The primary purpose of premedication in Meckel scintigraphy is to reduce the secretion of Tc-99m-pertechnetate into the gastric lumen. Thus, Tc-99m-pertechnetate, which is taken up by the gastric mucosa, cannot pass into the small intestine, and small ectopic gastric mucosa collections within the intestine can be visualized more easily. Second, to maintain any activity within the ectopic gastric mucosa and reduce its dispersion distally. However, there is a debate about the major benefit and mode of action (8). Pantoprazole belongs to the group of proton pump inhibitors (PPIs). The effects of PPIs on the gastric mucosa are similar to those of ranitidine (14).

However, there is no evidence that PPIs can be used for premedication in Meckel scintigraphy.

Our aim in this preclinical study was to measure Tc-99m-pertechnetate uptake in the stomach after pantoprazole premedication to investigate the potential of pantoprazole as premedication in Meckel scintigraphy.

## Materials and Methods

This preclinical study was approved by the Pamukkale University Animal Experimentation Ethics Committee (no: PAUHDEK-2021/48, date: 24.02.2022). National and international directives on animal experiments were followed. Animal gender was not considered a factor in the experimental design. All rabbits were housed in separate cages and fed ad libitum with 12-h day and night cycles at 25 °C during all procedures. Twelve New Zealand rabbits (*Oryctolagus cuniculus*) weighing 2150-2500 g were divided into two groups as Pantoprazole (n=6) and control (n=6). Pantoprazole group rabbits were injected with 1 mg/kg of Pantoprazole (Pulcet, Nobel ilaç, İstanbul) through the ear vein for three days. All rabbits were fasted for 4 h before scintigraphic imaging. Ketamine 35 mg/kg (Keta-control 25 mL, Doğa ilaç, İstanbul) and Xylazine 5 mg/kg (Control 100 mL, Doğa ilaç, İstanbul) were injected intramuscularly to provide general anesthesia before scintigraphic imaging. Ear vascular access was established in the pantoprazole group rabbits. 37 mBq/kg Tc-99m-pertechnetate was intravenously injected 1 h after pantoprazole injection. Scintigraphic imaging was performed using a dual-detector hybrid gamma camera (2.5 mA, 120 kVp; Philips Brightview XBT). Dynamic planar imaging was performed for 1 hour (5 min/frame; total 6 frame). After anesthesia application to the control group rabbits, an auricular vascular access was established and 37 MBq/kg Tc-99m-pertechnetate was injected and imaged in the same manner. A flow chart of the rabbit experiment is shown in Figure 1.



**Figure 1.** The flow chart of the rabbit experiment

All images were visually and quantitatively evaluated by an experienced nuclear medicine specialist. For quantitative analysis, regions of interest (ROI) were drawn from the stomach walls of all rabbits, and total counts were recorded. ROI areas obtained from the gastric wall were equal, and background correction was performed.

### Statistical Analysis

Data were analyzed using SPSS 24.0 package software (IBM, Armonk, NY, USA). Continuous variables are given as mean  $\pm$  standard deviation, and categorical variables are given as frequency and percentage. Because the groups did not follow a normal distribution, for independent group comparisons, we used the Mann-Whitney U test. A p-value of 0.05 was considered significant.

### Results

In the visual evaluation, increased Tc-99m-pertechnetate uptake was observed in the stomach wall of rabbits premedicated with pantoprazole compared with the control group rabbits. In the control group, the accumulation of Tc-99m-pertechnetate secreted from the stomach to the intestines was observed (Figure 2).

In the quantitative evaluation, when the gastric wall counts of the rabbits premedicated with pantoprazole for 3 days were compared with the control group rabbits, Tc-99m-pertechnetate uptake was found to be significantly higher in the stomach of premedicated rabbits ( $p=0.006$ ).

### Discussion

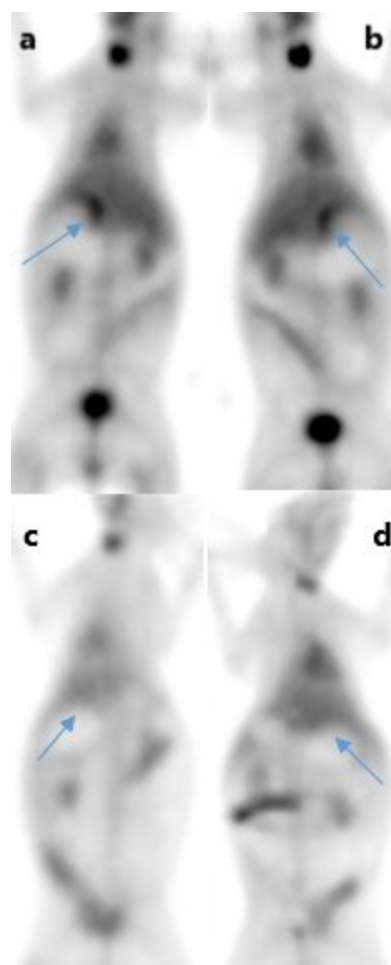
A New Zealand rabbit was selected for this experimental study. Histological, structural, and experimental studies on the stomach have reported that the gastric mucosa of rabbits and humans are generally similar, but there may be differences in the number and regional distribution of cell types (15). According to the findings of this experimental study, as a result of visual and quantitative evaluation, pantoprazole significantly increases Tc-99m-pertechnetate uptake in the stomach. There is no similar study in the literature. H<sub>2</sub> receptor blockers increase the sensitivity of Meckel scintigraphy. They reduce peptic secretion although the exact mechanism has not been elucidated. They delay the secretion of pertechnetate from parietal cells and mucus cells into the lumen. Therefore, H<sub>2</sub> receptor blockers increase the sensitivity of the Meckel scintigraphy study by causing higher radionuclide concentrations in the stomach and Meckel's diverticulum (5,9,10,11,16,17).

Pantoprazole is an irreversible proton pump (H<sup>+</sup>/K<sup>+</sup>-ATPase) inhibitor that reduces acid secretion from gastric parietal cells. Pantoprazole is believed to increase pertechnetate

uptake in the gastric mucosa by the same mechanism as H<sub>2</sub> receptor blockers (18). In our study, we used pantoprazole for 3 days as premedication. We performed imaging 1 h after pantoprazole injection on the fourth day. PPIs have a long half-life. The half-life of pantoprazole is 46 h. Not all proton pumps are inactivated by the first dose of the drug; three days of treatment is needed to reach the full acid inhibition potential (19).

### Study Limitations

Our study has a limitation. Because of their short half-lives, H<sub>2</sub> receptor blockers are more suitable as premedications for Meckel scintigraphy than PPIs. However, there is currently no parenteral or pediatric syrup form of any H<sub>2</sub> receptor blocker preparation. Therefore, the parenteral form of pantoprazole was preferred in our study.



**Figure 2.** Tc-99m-pertechnetate uptake in the stomach wall of the rabbits premedicated with i.v. pantoprazole in Tc-99m-pertechnetate scintigraphy (a,b; blue arrows), physiological Tc-99m-pertechnetate uptake is observed in the gastric wall of the control group rabbits (c,d; blue arrows)

**Table 1. Counts from the stomach wall rabbits premedicated with intravenous pantoprazole and control group**

	Pantoprazole (mean ± SD)	Control (mean ± SD)	p-value
Stomach	347719±58539	183514±55385	*0.006
SD: Standard deviation			

## Conclusion

As a result, with the prohibition of ranitidine by the FDA, the need for new drugs that can be used as premedication for Meckel's diverticulum scintigraphy has emerged. Pantoprazole increases the gastric wall uptake of pertechnetate after three days of premedication and is a potential drug that can be used for premedication in Meckel scintigraphy. The results need to be confirmed by clinical studies.

## Ethics

**Ethics Committee Approval:** This preclinical study was approved by the Pamukkale University Animal Experimentation Ethics Committee (no: PAUHDEK-2021/48, date: 24.02.2022). All national and international directives were complied with during the experiments.

**Informed Consent:** Animal experimental study.

## Authorship Contributions

Surgical and Medical Practices: A.G., S.D., Concept: A.G., Design: A.G., T.Ş., Data Collection or Processing: A.G., S.D., Analysis or Interpretation: T.Ş., D.Y., Literature Search: A.G., Writing: A.G., D.Y.

**Conflict of Interest:** No conflict of interest was declared by the authors.

**Financial Disclosure:** The authors declared that this study has received no financial support.

## References

- Park JJ, Wolff BG, Tollefson MK, Walsh EE, Larson DR. Meckel diverticulum: the Mayo Clinic experience with 1476 patients (1950-2002). *Ann Surg* 2005;241:529-533.
- Brown RL, Azizkhan RG. Gastrointestinal bleeding in infants and children: Meckel's diverticulum and intestinal duplication. *Semin Pediatr Surg* 1999;8:202-209.
- Samain J, Maeyaert S, Geusens E, Mussen E. Sonographic findings of Meckel's diverticulitis. *JBR-BTR* 2012;95:103.
- Datz FL, Christian PE, Hutson WR, Moore JG, Morton KA. Physiological and pharmacological interventions in radionuclide imaging of the tubular gastrointestinal tract. *Semin Nucl Med* 1991;21:140-152.
- Hosseinnezhad T, Shariati F, Treglia G, Kakhki VR, Sadri K, Kianifar HR, Sadeghi R. <sup>99m</sup>Tc-Pertechnetate imaging for detection of ectopic gastric mucosa: a systematic review and meta-analysis of the pertinent literature. *Acta Gastroenterol Belg* 2014;77:318-327.
- Sfakianakis GN, Conway JJ. Detection of ectopic gastric mucosa in Meckel's diverticulum and in other aberrations by scintigraphy: ii. indications and methods—a 10-year experience. *J Nucl Med* 1981;22:732-738.
- Jain TP, Sharma R, Chava SP, Das CJ. Pre-operative diagnosis of Meckel's diverticulum: report of a case and review of literature. *Trop Gastroenterol* 2005;26:99-101.
- Saremi F, Jadvar H, Siegel ME. Pharmacologic interventions in nuclear radiology: indications, imaging protocols, and clinical results. *Radiographics* 2002;22:477-490.
- Spottswood SE, Pfluger T, Bartold SP, Brandon D, Burchell N, Delbeke D, Fink-Bennett DM, Hodges PK, Jolles PR, Lassmann M, Maurer AH, Seabold JE, Stabin MG, Treves ST, Vljakovic M; Society of Nuclear Medicine and Molecular Imaging; European Association of Nuclear Medicine. SNMMI and EANM practice guideline for meckel diverticulum scintigraphy 2.0. *J Nucl Med Technol* 2014;42:163-169. Erratum in: *J Nucl Med Technol* 2016;44:51.
- Wu H, Zhao X, Li Y, Zhao R. Reconsideration of the primary and secondary diagnostic criteria of Meckel's diverticulum scintigraphy. A study of 93 confirmed cases. *Hell J Nucl Med* 2017;20:11-16.
- Vali R, Daneman A, McQuattie S, Shamma A. The value of repeat scintigraphy in patients with a high clinical suspicion for Meckel diverticulum after a negative or equivocal first Meckel scan. *Pediatr Radiol* 2015;45:1506-1514.
- White CM, Hernandez AV. Ranitidine and Risk of N-Nitrosodimethylamine (NDMA) Formation. *JAMA* 2021;326:225-227.
- White CM, Hernandez AV. Risk of N-Nitrosodimethylamine (NDMA) Formation With Ranitidine-Reply. *JAMA* 2021;326:2077-2078.
- Cheer SM, Prakash A, Faulds D, Lamb HM. Pantoprazole: an update of its pharmacological properties and therapeutic use in the management of acid-related disorders. *Drugs* 2003;63:101-133.
- Yaman M, Girgin A. Electron Microscopic Investigations of Rabbit Stomach Fundic Mucosa on the Prenatal and Postnatal Periods. *FÜ.Sağ. Bil.Vet.Derg* 2005;19:37-42.
- Kiratli PO, Aksoy T, Bozkurt MF, Orhan D. Detection of ectopic gastric mucosa using <sup>99m</sup>Tc pertechnetate: review of the literature. *Ann Nucl Med* 2009;23:97-105.
- Diamond RH, Rothstein RD, Alavi A. The role of cimetidine-enhanced technetium-<sup>99m</sup>-pertechnetate imaging for visualizing Meckel's diverticulum. *J Nucl Med* 1991;32:1422-1424.
- Sagar VV, Piccone JM. The effect of cimetidine on blood clearance, gastric uptake, and secretion of <sup>99m</sup>Tc-pertechnetate in dogs. *Radiology* 1981;139:729-731.
- Shin JM, Munson K, Vagin O, Sachs G. The gastric HK-ATPase: structure, function, and inhibition. *Pflugers Arch* 2009;457:609-622. Erratum in: *Pflugers Arch* 2011;461:399.