



# Unusual Case of Pseudomembranous Colitis Presenting as Fever of Unknown Origin Diagnosed by Tc-99m-HMPAO-labeled Leukocytes SPECT/CT

Nedeni Bilinmeyen Ateş ile Prezente olan ve Tc-99m-HMPAO İşaretli Lökosit SPECT/CT ile Teşhis Edilen Olağan Dışı Psödomembranöz Enterokolit Olgusu

✉ Rosanna Del Carmen Zambrano-Infantino<sup>1</sup>, ✉ Jean Félix Piñerúa-González<sup>2</sup>, ✉ Noelia Alvarez-Mena<sup>1</sup>, ✉ Sandra Izquierdo-Santervás<sup>2</sup>, ✉ Noelia Alcaide<sup>2</sup>, ✉ Maria Garcia-Aragon<sup>1</sup>, ✉ Ricardo Ruano-Pérez<sup>1</sup>

<sup>1</sup>Hospital Clínico Universitario de Valladolid, Department of Nuclear Medicine, Valladolid, Spain

<sup>2</sup>Hospital Clínico Universitario de Valladolid, Department of Gastroenterology, Valladolid, Spain

## Abstract

The fever of unknown origin (FUO) represents a complex diagnostic challenge due to the wide range of etiologies that could cause it, including neoplastic, infectious, rheumatic/inflammatory, and miscellaneous disorders. Several nuclear medicine techniques have proven to be valuable tools for guiding etiologic diagnosis in the setting of FUO. One of these is technetium-99m (Tc-99m)-hexamethylpropylene amine oxime (HMPAO)-labeled leukocyte scintigraphy, which is a diagnosis method that allows in most cases the localization and evaluation of the extension of an occult infection. This paper presents an uncommon case of pseudomembranous colitis without diarrhea as etiology of FUO diagnosed by Tc-99m-HMPAO-labeled leukocytes.

**Keywords:** Pseudomembranous colitis, fever of unknown origin, Tc-99m-HMPAO, single-photon emission computed tomography, radionuclide imaging

## Öz

Nedeni bilinmeyen ateş (NBA), buna neden olabilecek neoplastik, enfeksiyöz, romatizmal/enflamatuvar ve çeşitli bozukluklar dahil olmak üzere çok çeşitli etiyolojiler nedeniyle tanısı zor bir durumdur. Birkaç nükleer tıp tekniğinin, NBA'da etiyolojik tanıya rehberlik etmek için değerli araçlar olduğu kanıtlanmıştır. Bunlardan biri, çoğu durumda gizli bir enfeksiyonun lokalizasyonuna ve yayılımının değerlendirilmesine olanak tanıyan bir tanı yöntemi olan teknesyum-99m (Tc-99m)-heksametilpropilen amin oksim (HMPAO) işaretli lökosit sintigrafisidir. Bu yazıda, Tc-99m-HMPAO işaretli lökositler ile teşhis edilen NBA etiyolojisi olarak diyarenin eşlik etmediği nadir bir psödomembranöz kolit olgusu sunulmaktadır.

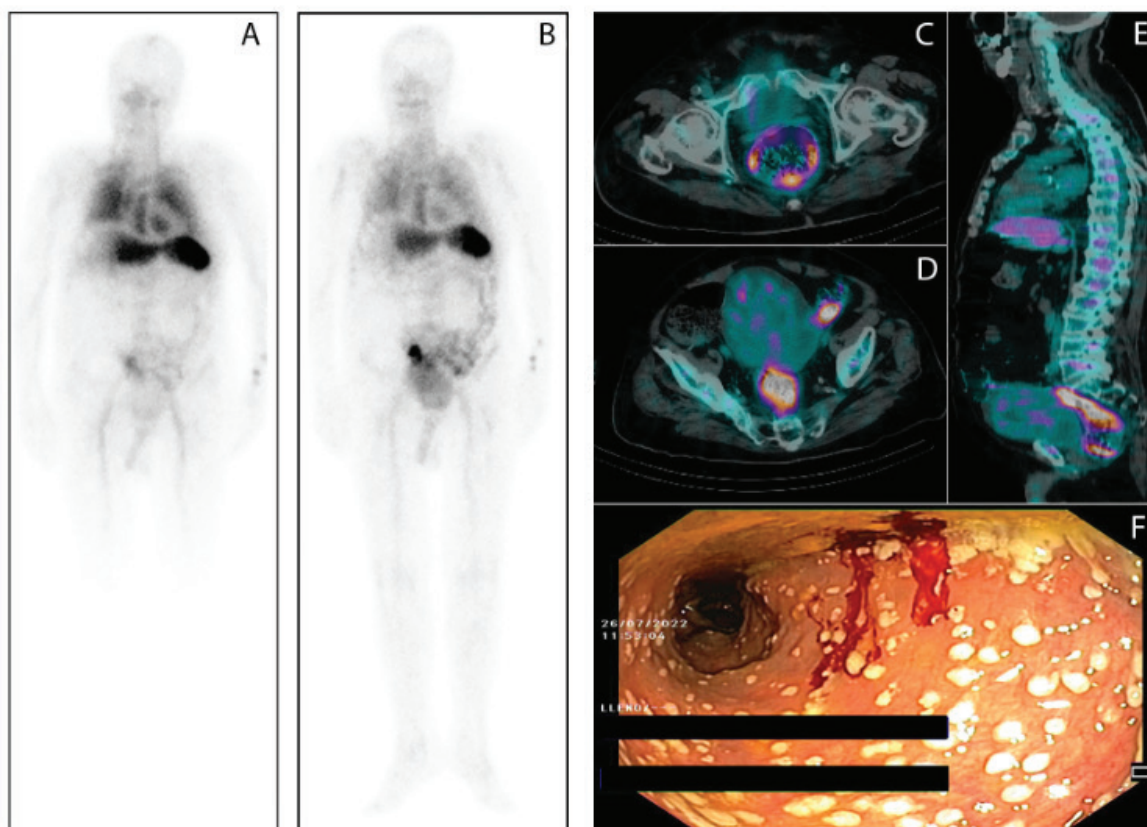
**Anahtar kelimeler:** Psödomembranöz kolit, nedeni bilinmeyen ateş, Tc-99m-HMPAO, tek foton emisyonlu bilgisayarlı tomografi, radyonüklid görüntüleme

**Address for Correspondence:** Rosanna Del Carmen Zambrano-Infantino MD, Hospital Clínico Universitario de Valladolid, Department of Nuclear Medicine, Valladolid, Spain

**Phone:** +983420003 **E-mail:** rosannamedicina@hotmail.com ORCID ID: orcid.org/0000-0001-6876-5948

**Received:** 29.08.2022 **Accepted:** 25.12.2022

©Copyright 2023 by the Turkish Society of Nuclear Medicine / Molecular Imaging and Radionuclide Therapy published by Galenos Publishing House. Licensed by Creative Commons Attribution-NonCommercial-NoDerivatives 4.0 (CC BY-NC-ND) International License.



**Figure 1.** An 88-year-old man with a 1-month daily fever  $>38.5^{\circ}\text{C}$  and hyporexia. All other systems were reviewed and were negative. The patient had a past medical history of arterial hypertension and type 2 diabetes mellitus. There were no remarkable findings in the physical examination for a body temperature of  $38.9^{\circ}\text{C}$ . At admission, the laboratory findings were as follows: hemoglobin, 9.8 gr/dL; white blood cell count,  $18,840/\text{mm}^3$ ; erythrocyte sedimentation rate,  $10^3$  mm/h; C-reactive protein, 215 mg/L; and procalcitonin, 1.38 ng/mL. Blood and urine cultures, viral serology, immunological profile, abdominal ultrasound, chest radiology, and echocardiogram were negative. Technetium-99m (Tc-99m)-hexamethylpropylene amine oxime (HMPAO)-labeled leukocytes single-photon emission computed tomography/computed tomography (SPECT/CT) was requested to identify the location of a probable occult infection. Planar images of the whole body were obtained after 30 min (A) and 3 h postinjection with thoraco abdomino pelvic SPECT/CT at 3 hours post injection. Planar images of the whole body at 3 h post-injection of Tc-99m-HMPAO-labeled leukocytes revealed increased uptake in the rectum and sigmoid colon (B). SPECT/CT fusion images showed pathological Tc-99m-HMPAO-labeled leukocytes uptake in the walls of the rectum, sigmoid, and descending colon (C, D, E). In view of the previous findings, colonoscopy was performed revealing multiple white-grey small plaques with mild erythema of the surrounding mucosa along the rectosigmoid and descending colon (F). These lesions were suggestive of pseudomembranous colitis, so rectal samples for microbiological studies and mucosal biopsies were taken. Polymerase chain reaction assays detected toxinogenic *Clostridium difficile* in the clinical isolates. Histological examination showed isolated focuses of ulceration and crypts with reactive changes and focal atrophy, neutrophil infiltration, and hyalinization of the lamina propria. The patient was treated with oral vancomycin with subsequent cessation of fever and improvement of laboratory parameters. Fever of unknown origin (FUO) represents a complex diagnostic challenge due to the wide range of causes that could cause it including neoplastic, infectious, rheumatic/inflammatory, and miscellaneous disorders. This entity is defined by three criteria: 1) body temperature  $\geq 38.3^{\circ}\text{C}$ , 2) minimum duration of 3 weeks, and 3) etiology unidentified despite an extended work-up (1). There are several nuclear medicine techniques that are valuable tools for guiding etiologic diagnosis in the setting of FUO (2). One of these is Tc-99m-HMPAO labeled leukocyte scintigraphy, which is a diagnosis method that allows in most cases the localization and evaluation of the extension of an occult infection (3,4). The usual clinical picture of pseudomembranous colitis includes diarrhea (the most common symptom), abdominal pain, fever, and elevated white blood cell counts. The absence of diarrhea is very infrequent in this setting, making its diagnosis difficult. Some unusual presentation forms include fulminant colitis, toxic megacolon, perforation, and intestinal pseudo-obstruction (5). This paper illustrated an uncommon case of pseudomembranous colitis presenting as FUO in which Tc-99m-HMPAO-labeled leukocytes were the key to achieving the diagnosis.

## Ethics

**Informed Consent:** Informed consent was obtained by patient.

**Peer-review:** Externally peer-reviewed.

## Authorship Contribution

Surgical and Medical Practices: S.I-S., N.A., Concept: R.D.C.Z-I., Design: R.D.C.Z-I., J.FP-G., Data Collection or Processing: R.D.C.Z-I., J.FP-G., Analysis or Interpretation: R.D.C.Z-I., J.FP-G., N.A-M., M.G-A., R.R-P., Literature Search: R.D.C.Z-I., M.G-A., Writing: R.D.C.Z-I., J.FP-G.

**Conflict of Interest:** No conflict of interest was declared by the authors.

**Financial Disclosure:** The authors declared that this study received no financial support.

## References

1. Cunha BA, Lortholary O, Cunha CB. Fever of unknown origin: a clinical approach. *Am J Med* 2015;128:1138.
2. Cosma L, Frantellizzi V, Pontico M, De Vincentis G. Unexpected detection of abscessualized lung carcinoma on Tc-99m-HMPAO-labeled leukocytes scintigraphy misdiagnosed on chest computed tomography. *Mol Imaging Radionucl Ther* 2021;30:60-62.
3. de Vries EF, Roca M, Jamar F, Israel O, Signore A. Guidelines for the labelling of leucocytes with (99m)Tc-HMPAO. Inflammation/infection taskgroup of the European Association of Nuclear Medicine. *Eur J Nucl Med Mol Imaging* 2010;37:842-848.
4. Sc Schönau V, Vogel K, Englbrecht M, Wacker J, Schmidt D, Manger B, Kuwert T, Schett G. The value of 18F-FDG-PET/CT in identifying the cause of fever of unknown origin (FUO) and inflammation of unknown origin (IUO): data from a prospective study. *Ann Rheum Dis* 2018;77:70-77.
5. Sheikh RA, Yasmeeen S, Pauly MP, Trudeau WL. Pseudomembranous colitis without diarrhea presenting clinically as acute intestinal pseudo-obstruction. *J Gastroenterol* 2001;36:629-632.