



Mesenteric Panniculitis Appears as Metastatic Disease on ¹⁸F-FDG-PET/CT Scan

¹⁸F-FDG-PET/BT Görüntülemesinde Metastaz Düşündüren Mezenterik Pannikülit Olgusu

Özgül Ekmekçiöğlü¹, Selim Bakan², Kerim Sönmezoğlü³

¹University of Health Sciences Turkey, Şişli Hamidiye Etfal Training and Research Hospital, Clinic of Nuclear Medicine, İstanbul, Turkey

²İstanbul University-Cerrahpaşa, Cerrahpaşa Faculty of Medicine, Department of Radiology, İstanbul, Turkey

³İstanbul University-Cerrahpaşa, Cerrahpaşa Faculty of Medicine, Department of Nuclear Medicine, İstanbul, Turkey

Abstract

Mesenteric panniculitis is a rare benign inflammatory process involving mesenteric adipose tissue and the pathogenesis is still unknown. It may present ¹⁸Fluorine-fluorodeoxyglucose (¹⁸F-FDG) uptake and appear like a malign tumor or metastatic disease. We report a case of 47 year-old woman with serous ovarian adenocarcinoma demonstrating intense ¹⁸F-FDG uptake and hyperdense nodularity in mesenteric fatty tissue on post-chemotherapy positron emission tomography/computed tomography imaging. The serum tumor marker (CA-125) level was within the normal range. A correlative magnetic resonance imaging highlighted the diagnosis of mesenteric panniculitis that was also confirmed by clinical follow-up.

Keywords: Mesenteric panniculitis, PET/CT, ovary carcinoma

Öz

Mezenterik pannikülit mezenterik yağlı dokunun nadir görülen ve benign karakterli enflamatuvar hastalığı olup patogenezi halen tam olarak bilinmemektedir. ¹⁸Flor-florodeoksiglukoz (¹⁸F-FDG) tutulumu gösterip, malignite veya metastatik hastalık gibi görünebilir. Seröz tipte over adenokarsinom tanısı bulunan 47 yaşında kadın hastanın kemoterapi sonrası pozitron emisyon tomografisi/bilgisayarlı tomografi görüntülemesinde mezenterik yağlı dokuda hiperdens nodüler görünüm ve ¹⁸F-FDG tutulumu saptandı. Serum tümör marker (CA-125) normal düzeyde bulunan olguda, sonrasında yapılan manyetik rezonans görüntülemesinde mezenterik pannikülit tanısı takipte ve klinik olarak da doğrulandı.

Anahtar kelimeler: Mezenterik pannikülit, PET/BT, over kanseri

Address for Correspondence: Özgül Ekmekçiöğlü MD, University of Health Sciences Turkey, Şişli Hamidiye Etfal Training and Research Hospital, Clinic of Nuclear Medicine, İstanbul, Turkey

Phone: +90 212 373 52 14 **E-mail:** ozgulek@gmail.com ORCID ID: orcid.org/0000-0002-3313-8087

Received: 13.11.2020 **Accepted:** 13.02.2021

©Copyright 2022 by Turkish Society of Nuclear Medicine
Molecular Imaging and Radionuclide Therapy published by Galenos Yayınevi.

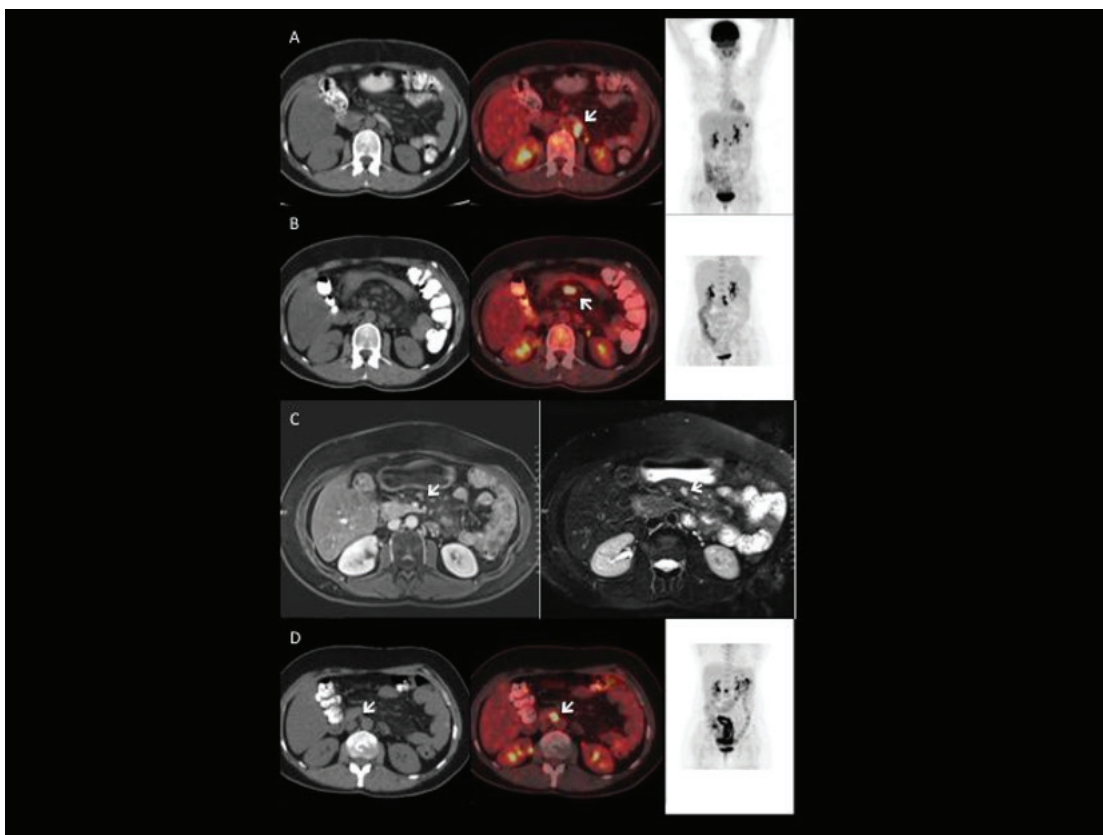


Figure 1. The first positron emission tomography/computed tomography (PET/CT) scan was performed for restaging purposes due to increased (CA-125) level (70 U/mL) is shown in the upper row. There were several enlarged lymph nodes with intense ^{18}F -fluorodeoxyglucose (^{18}F -FDG) uptake in the left aortic and interaortocaval regions [maximum standardized uptake value (SUV_{max}): 11.6] of the abdomen (A). Post-therapeutic PET/CT study done after 8 cycles of chemotherapy is seen in the second row and showed complete metabolic regression of all metastatic lesions seen on the previous scan. However, a few new lesions with intense ^{18}F -FDG accumulation were observed in the mesenteric region (SUV_{max} : 13.4) (B), despite normal ranged tumor markers at that time. To provide further lesion characterization, a magnetic resonance imaging (MRI) was performed and revealed hyperintense nodular lesions in the superior mesenteric region on T2 weighted fat saturated images, all of which also demonstrated contrast enhancement with no vessel invasion on T1 weighted fat saturated post-contrast images. These findings were suggestive of mesenteric panniculitis, rather than malignancy (C) (1). After one year clinical follow-up without any treatment and any severe clinical problem, PET/CT scan was repeated as CA-125 levels increased up to 192 U/mL and showed multiple hypermetabolic lymphadenopathies (SUV_{max} : 21.6) in the interaortocaval area and some hypermetabolic implants in the peritoneal surfaces of the abdomen, suggesting recurrent disease. On the contrary, mesenteric ^{18}F -FDG uptake that was detected on previous PET/CT scan due to panniculitis was completely resolved, as reported in the most cases in other reports (D) (2). The etiology of mesenteric panniculitis is still unknown but the history of abdominal trauma or surgical operation has been reported. Other causes may also be responsible (3,4). The CT findings are reported to vary depending on the stage of the disease but even mesenteric vessels are displaced and surrounded by the involved fat, there is no vessel invasion. Thereby MRI will be more useful for evaluation of vessel invasion and differential diagnosis (5,6). In a study, a group of 19 patients with a history of different malignancies was investigated by ^{18}F -FDG-PET/CT study for the recent diagnosis of mesenteric panniculitis on abdominal CT imaging. Among these, 11 patients with no ^{18}F -FDG uptake in the abdomen had no active malignancy during follow-up, whereas 7 of 8 patients who had increased ^{18}F -FDG uptake were associated with tumor involvement. Therefore, it was concluded that ^{18}F -FDG PET/CT scan can be used to differentiate malignant involvement in patients with mesenteric panniculitis (7). However, there was one patient in that study, who was diagnosed with rectal carcinoma, with no tumor involvement and false positive ^{18}F -FDG uptake, similar to our case. Another case with non-Hodgkin lymphoma has also demonstrated false ^{18}F -FDG uptake that was compatible with mesenteric panniculitis (8). In conclusion, it should be kept in mind that increased ^{18}F -FDG uptake in mesenteric region might be related to inflammatory lesions like panniculitis.

Ethics

Informed Consent: It was obtained from the patient.

Peer-review: Externally and internally peer-reviewed.

Authorship Contributions

Surgical and Medical Practices: K.S., S.B., Concept: Ö.E., S.B., K.S., Design: Ö.E., K.S., Data Collection or Processing: Ö.E., Analysis or Interpretation: S.B., K.S., Literature Search: Ö.E., Writing: O.E.

References

1. Biscaldi E, Romairone E, Rollandi GA. Regarding six cases of mesenteric panniculitis: US, spiral CT, magnetic resonance. *Radiol Med* 2002;103:511-518.
2. Delgado Plasencia L, Rodríguez Ballester L, López-Tomassetti Fernández EM, Hernández Morales A, Carrillo Pallarés A, Hernández Siverio N. Panniculitis mesentérica: experiencia en nuestro centro [Mesenteric panniculitis: experience in our center]. *Rev Esp Enferm Dig* 2007;99:291-297.
3. Emory TS, Monihan JM, Carr NJ, Sobin LH. Sclerosing mesenteritis, mesenteric panniculitis and mesenteric lipodystrophy: a single entity? *Am J Surg Pathol* 1997;21:392-398.
4. Pahuja D, Eustace M, Chadha P. Mesenteric panniculitis: an unusual initial presentation of systemic lupus erythematosus (SLE). *Internet J Rheumatol* 2005;2:1-5.
5. Mata JM, Inaraja L, Martín J, Olazabal A, Castilla MT. CT features of mesenteric panniculitis. *J Comput Assist Tomogr* 1987;11:1021-1023.
6. Kobayashi S, Takeda K, Tanaka N, Hirano T, Nakagawa T, Matsumoto K. Mesenteric panniculitis: MR findings. *J Comput Assist Tomogr* 1993;17:500-502.
7. Zissin R, Metser U, Hain D, Even-Sapir E. Mesenteric panniculitis in oncologic patients: PET-CT findings. *Br J Radiol* 2006;79:37-43.
8. Sideras PA, Patil V, Li Z, Heiba S, Kostakoglou L. PET-CT of mesenteric panniculitis: a potential confounder of lymphoma. *Radiography* 2015;21:51-53.