Interesting Image

Mol Imaging Radionucl Ther **DOI:***10.4274/mirt.galenos.2026.98370*

A Silent Traveler: ^{18}F-FDG-negative Intravascular Leiomyomatosis with Intracardiac Extension

Sessiz Bir Yolcu: İntrakardiyak Uzantılı ^{18}F-FDG-negatif İntravasküler Leiomyomatozis

Adnan Liaqat, Sana Munir Gill, Hajira Ilyas

Shaukat Khanum Memorial Cancer Hospital and Research Center, Clinic of Nuclear Medicine, Peshawar, Pakistan

Abstract

Intravascular leiomyomatosis (IVL) is a rare entity, which may present with leiomyomas. IVL is characterized by intravascular proliferation of smooth muscle cells. It may develop independently or originate from uterine leiomyoma and extend into the adjacent pelvic veins with possible extension into the inferior vena cava and beyond. It may or may not be symptomatic and often is an incidental finding on radiological imaging. To evaluate its extent, computed tomography (CT) and magnetic resonance imaging (MRI) play an important role. We illustrate an interesting case in which non avid pelvic masses with filling defect in pelvic veins extending into the inferior vena cava and right atrium was detected on oncological ^{18}F-FDG PET/CT acquired for known right parotid gland mucoepidermoid carcinoma. Later, post surgical histopathology revealed leiomyomas and IVL.

Keywords: Intravascular leiomyomatosis, leiomyoma, ^{18}F-FDG PET/CT

Öz

İntravasküler leiomyomatozis (IVL), leiomyomlarla birlikte ortaya çıkabilen nadir bir durumdur. IVL, düz kas hücrelerinin intravasküler proliferasyonu ile karakterizedir. Bağımsız olarak gelişebilir veya uterus leiomyomundan kaynaklanarak komşu pelvik venlere, muhtemelen inferior vena cava'ya ve ötesine uzanabilir. Semptomatik olabilir veya olmayabilir ve genellikle radyolojik görüntülemede tesadüfi bir bulgudur. Yayılımını değerlendirmede bilgisayarlı tomografi (BT) ve manyetik rezonans görüntüleme (MRG) önemli bir rol oynar. Bilinen sağ parotis bezi mukoepidermoid karsinomu için çekilen onkolojik ^{18}F-FDG PET/BT'de saptanan, inferior vena cava ve sağ atriyuma uzanan, pelvik venlerde dolum defektinin eşlik ettiği, tutulum göstermeyen pelvik kitleleri olan ilginç bir olgu bildiriyoruz. Ameliyat sonrası histopatolojik incelemede leiomyomlar ve intravasküler leiomyomatozis saptanmıştır.

Anahtar Kelimeler: İntravasküler leiomyomatozis, leiomyoma, ^{18}F-FDG PET/BT

Address for Correspondence: Sana Munir Gill, Shaukat Khanum Memorial Cancer Hospital and Research Center, Clinic of Nuclear Medicine, Peshawar, Pakistan

E-mail: sanamunir@skm.org.pk **ORCID ID:** orcid.org/0000-0002-1598-6162

Received: 07.04.2026 **Accepted:** 08.07.2026 **Epub:** 25.11.2026

Cite this article as: Liaqat A, Gill SM, Ilyas H. A silent traveler: ^{18}F-FDG-negative intravascular leiomyomatosis with intracardiac extension. Mol Imaging Radionucl Ther. [Epub Ahead of Print]

Copyright© 2027 The Author(s). Published by Galenos Publishing House on behalf of the Turkish Society of Nuclear Medicine.
This is an open access article under the Creative Commons Attribution-NonCommercial-NoDerivatives 4.0 (CC BY-NC-ND) International License.

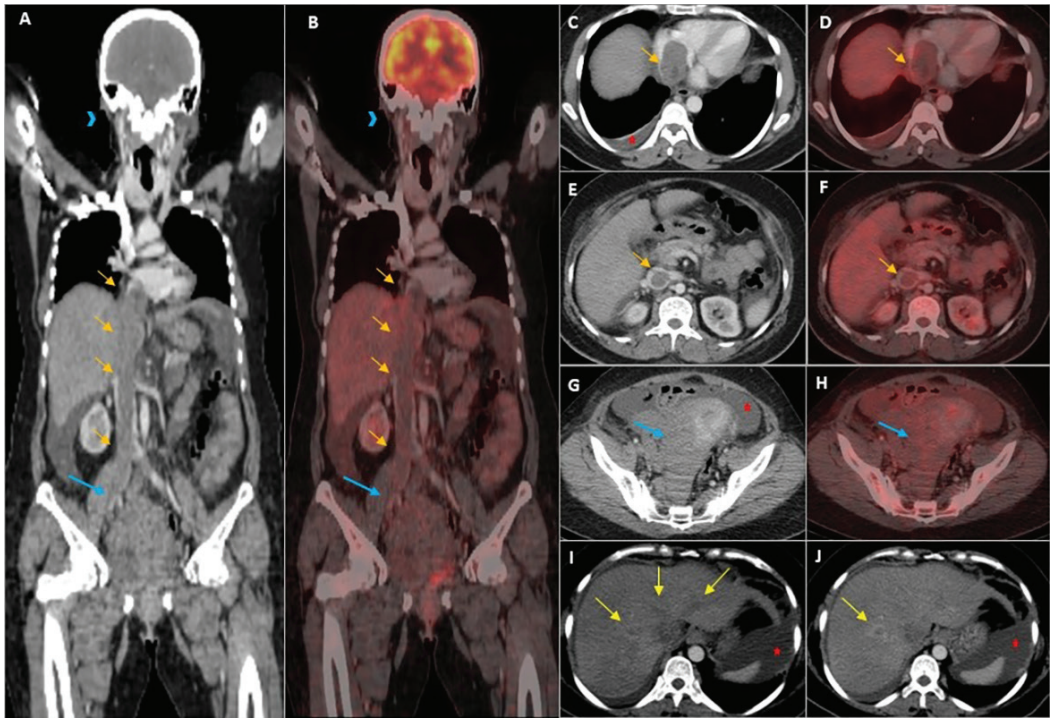

Figure 1. A 47-year-old female was referred to the Nuclear Medicine Department for a follow-up ^{18}F-fluorodeoxyglucose positron emission tomography/computed tomography (^{18}F-FDG PET/CT) after right parotidectomy and nodal dissection, followed by radiotherapy, for mucoepidermoid carcinoma. Three months later, PET/CT was performed to assess residual or recurrent disease. Following standard patient preparation, ^{18}F-FDG PET/CT images were acquired from the head to the mid-thigh after 60 minutes of uptake. No evidence of ^{18}F-FDG avid residual disease was seen in the right parotidectomy bed (A, B: CT-only and fused coronal views; arrowhead). However, incidental ^{18}F-FDG-non-avid pelvic masses were noted (A, B coronal and G, H axial views; blue arrows) along with a non-avid filling defect in the pelvic veins, more prominent in the right external iliac vein extending into the right common iliac veins, inferior vena cava, and right atrium (A-H; green arrows). Further extension into the hepatic veins was also demonstrated (arrows I-J). Mild abdominopelvic ascites, a small right-sided pleural effusion, and subtle edema involving the lower pelvic wall and adjacent lower limbs were also present (C, D, I, J; asterisks). Subsequently, the patient underwent hysterectomy with bilateral salpingo-oophorectomy and excisional biopsy of the intravascular soft tissue. Histopathological examination of the uterine wall and adjacent nodules revealed smooth muscle cells arranged in fascicles and storiform patterns, growing within venous lumina. These formed polypoid intraluminal projections within dilated vascular channels and compressed the surrounding vessel walls. The nodules were lined by intact endothelial cells with preservation of the muscular vessel layer. No cytologic atypia, increased mitotic activity, or tumor necrosis were identified. Separate leiomyomas showed well-circumscribed spindle-cell proliferations composed of cells with evenly spaced, oval nuclei and ill-defined cytoplasmic borders. Immunohistochemistry demonstrated positivity for alpha-smooth muscle actin and Desmin, negativity for CD10, and retention of fumarate hydratase expression. The findings were consistent with benign intravenous leiomyomatosis (IVL) originating from a uterine leiomyoma.

IVL is a rare benign smooth muscle neoplasm that affects approximately 0.25-0.41% of women with uterine leiomyomas, with fewer than 750 cases reported worldwide up to 2020 (1,2). It is most commonly encountered in pre or perimenopausal women with a history of uterine fibroids (3). It is thought to arise from either a uterine leiomyoma or from the smooth muscle of the venous wall and can extend through the pelvic venous system into the IVC and even the heart.

^{18}F-FDG is the most widely used PET tracer in the world with uptake higher in malignant tumors due to over expression of GLUT receptors; hence it is used as a surrogate marker of increased metabolic activity and aggressiveness of tumors (4). Benign lesions such as IVL are low-grade and do not show significant metabolic activity. Although PET/CT is mainly used in the oncological setting, its CT component provides important anatomical details that can reveal incidental non-^{18}F-FDG-avid findings. Clinicians interpreting the scans must not limit attention to ^{18}F-FDG avid lesions only, as hybrid nuclear scans, such as PET/CT, often incidentally detect benign but clinically significant conditions, including IVL, which, if left untreated, can have major health implications. IVL's tendency to spread through the vessels into the heart and even pulmonary vessels can lead to life threatening arrhythmias, heart failure and various other complications (5,6).

In the present case, extension into the hepatic veins represented an uncommon pattern of disease spread. IVL may be associated with ascites, either in isolation or secondary to hepatic vein involvement leading to Budd–Chiari syndrome. Pleural effusion is less typical but may occur in association with benign pelvic tumors as part of pseudo-Meigs' syndrome (7,8). This case highlights the importance of carefully reviewing the CT component of hybrid PET/CT studies in addition to the metabolic findings, as recognition of such incidental but potentially life-threatening conditions can significantly influence patient management and outcomes.

Ethics

Informed Consent: The study was approved by Clinical Research Office/Institutional Review Board of Shaukat Khanum Memorial Cancer Hospital and Research Center; Lahore and a waiver of informed consent was obtained from the ethics committee.

Footnotes

Authorship Contributions

Surgical and Medical Practices: A.L., S.M.G., H.I., Concept: S.M.G., H.I., Design: S.M.G., H.I., Data Collection or Processing: A.L., S.M.G., Analysis or Interpretation: S.M.G., H.I., Literature Search: A.L., S.M.G., H.I., Writing: A.L., S.M.G., H.I.

Conflict of Interest: No conflicts of interest were declared by the authors.

Financial Disclosure: The authors declare that this study has received no financial support.

References

1. Sarra BL, Ghalleb M, Bouida MA, Rachdi MM, Ayedi MA, Dhieb TB. Case report: benign yet aggressive: intravascular extension of leiomyoma. Int J Surg Case Rep. 2025;134:111745.
2. Lim WH, Lamaro VP, Sivagnanam V. Manifestation and management of intravenous leiomyomatosis: a systematic review of the literature. Surg Oncol. 2022;45:101879.
3. Jiang T, Yang Y, Wang L. Intravascular leiomyomatosis in postmenopausal woman: a case report. Front Med (Lausanne). 2025;12:1517261.
4. Buck AK, Reske SN. Cellular origin and molecular mechanisms of ^{18}F-FDG uptake: is there a contribution of the endothelium? J Nucl Med. 2004;45:461-463.
5. Amabile A, Hong Y, Brown JA, Jacquemyn X, Lacomis J, Lee JE, Levenson J, Boisen ML, Kliner D, Toma C, Madigan M, Humar A, Christie N, Serna-Gallegos D, Bonatti J. Robotically-assisted resection of leiomyomatosis in the inferior vena cava with right atrial and ventricular extension. Am J Cardiol. 2026;264:72-75.
6. Atakul O, Temiz BE, Yilan BS, Cengiz M, Zaim OC, Tuncer ZS, Basaran D, Akgör U, Gültekin M. Rare presentation of intravenous leiomyomatosis: institutional experience of four complex cases. International Journal of Gynecological Cancer. 2026;36:104171.
7. Migishima F, Jobo T, Hata H, Sato R, Ikeda Y, Arai M, Kuramoto H. Uterine leiomyoma causing massive ascites and left pleural effusion with elevated CA 125: a case report. J Obstet Gynaecol Res. 2000;26:283-287.
8. Gan J, Ma X, Shao J, Wang J, Cao D. Intravenous leiomyomatosis presenting as Budd-Chiari syndrome: a case report and literature review. Orphanet J Rare Dis. 2025;20:49.