Interesting Image

Mol Imaging Radionucl Ther **DOI:***10.4274/mirt.galenos.2026.89090*

Primary Neurolymphomatosis with Multiple Neural and Systemic Lesions Depicted by Digital ^{18}F-FDG-PET/CT

Dijital ^{18}F-FDG-PET/BT ile Gösterilen Çoklu Sinir ve Sistemik Lezyonların Eşlik Ettiği Primer Nörolenfomatozis

Yusuke Manabe, Koichiro Kaneko, Kosuke Hida, Kengo Yoshimitsu

Department of Radiology, Fukuoka University Hospital, Fukuoka, Japan

Abstract

Primary neurolymphomatosis (NL) is a rare manifestation of malignant lymphoma defined by neural involvement present at diagnosis. The increasing use of magnetic resonance imaging and ^{18}F-fluorodeoxyglucose (^{18}F-FDG) positron emission tomography/computed tomography (PET/CT) has improved recognition of NL. We report a case of a 73-year-old Japanese man with histologically confirmed diffuse large B-cell lymphoma, whose pretreatment ^{18}F-FDG-PET/CT showed multiple lesions in cranial, spinal, and peripheral nerves, as well as systemic involvement (including lymph nodes, adrenal glands, testes, the right knee joint, and lower-limb bones), thus demonstrating both neural and widespread extranodal disease.

Keywords: Primary neurolymphomatosis, multiple neural involvement, systemic involvement, digital ^{18}F-FDG- PET/CT

Öz

Primer nörolenfomatozis (NL), tanı sırasında sinir tutulumunun bulunmasıyla tanımlanan, malign lenfomanın nadir bir bulgusudur. Manyetik rezonans görüntüleme ve ^{18}F-florodeoksiglukoz (^{18}F-FDG) ile pozitron emisyon tomografisi/bilgisayarlı tomografinin (PET/BT) giderek daha yaygın kullanılması, NL'nin tanınmasını kolaylaştırmıştır. Histopatolojik olarak diffüz büyük B hücreli lenfoma tanısı doğrulanmış 73 yaşındaki Japon bir erkek hastayı sunuyoruz. Hastanın tedavi öncesi ^{18}F-FDG-PET/BT incelemesinde kraniyal, spinal ve periferik sinirlerde çok sayıda lezyonun yanı sıra lenf düğümleri, adrenal bezler, testisler, sağ diz eklemi ve alt ekstremite kemiklerini içeren sistemik tutulum saptanmış; böylece hem sinir tutulumu hem de yaygın ekstranodal hastalık gösterilmiştir.

Anahtar Kelimeler: Primer nörolenfomatozis, çoklu sinir tutulumu, sistemik tutulum, dijital ^{18}F-FDG-PET/BT

Address for Correspondence: Koichiro Kaneko, Department of Radiology, Fukuoka University Hospital, Fukuoka, Japan
E-mail: kkaneko-kyu@umin.ac.jp **ORCID ID:** orcid.org/0000-0002-5046-2444
Received: 03.02.2026 **Accepted:** 11.10.2026 **Epub:** 25.11.2026

Cite this article as: Manabe Y, Kaneko K, Hida K, Yoshimitsu K. Primary neurolymphomatosis with multiple neural and systemic lesions depicted by digital ^{18}F-FDG-PET/CT. Mol Imaging Radionucl Ther. [Epub Ahead of Print]

Copyright© 2026 The Author(s). Published by Galenos Publishing House on behalf of the Turkish Society of Nuclear Medicine.
This is an open access article under the Creative Commons Attribution-NonCommercial-NoDerivatives 4.0 (CC BY-NC-ND) International License.

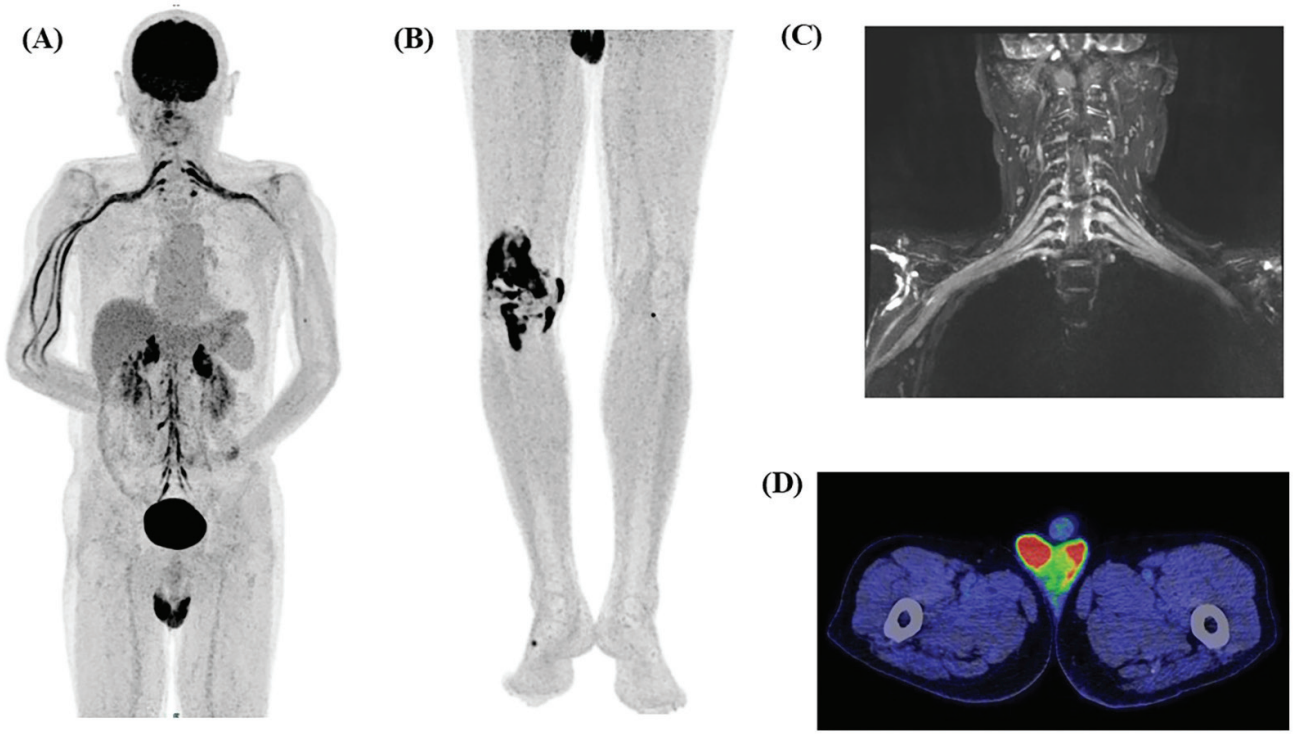

Figure 1. A 73-year-old Japanese man presented with oculomotor dysfunction, facial disorder, and peripheral neuropathy in the extremities, along with a markedly elevated serum soluble interleukin-2 receptor level of 2,440 U/mL. Clinical suspicion of neurolymphomatosis (NL) prompted a pretreatment ^{18}F-fluorodeoxyglucose positron emission tomography/computed tomography (^{18}F-FDG-PET/CT) (Biograph Vision 600, Siemens Healthineers) examination.

(A) Maximum-intensity projection (MIP) of the ^{18}F-FDG-PET image revealed intense ^{18}F-FDG uptake along the bilateral brachial plexuses, extending to the right radial, median, and ulnar nerves, and along the lumbar and sacral plexuses. Additional intense uptake was observed in the retroperitoneal lymph nodes, the bilateral adrenal glands, and the testes.

(B) MIP of the lower-extremity PET image demonstrated ^{18}F-FDG avid lesions in the right knee joint, the left tibia, and the left third metatarsal bone.

(C) Coronal 3D turbo spin-echo short-tau inversion-recovery (3D-TSE-STIR) magnetic resonance imaging (MRI) MIP showed linear thickening of the bilateral brachial plexus from the trunks through the cervical nerve roots.

(D) An axial PET/CT fused image revealed high ^{18}F-FDG uptake in the bilateral testes [maximum standardized uptake value (SUV_{max}) = 8.8]. Following a left high-orchiectomy, histological evaluation established a diagnosis of diffuse large B-cell lymphoma. B-cell non-Hodgkin lymphoma is closely associated with NL; diffuse large B-cell lymphoma is the most common NL histology (1,2). Whole-body ^{18}F-FDG-PET/CT is a highly sensitive imaging technology that can contribute to the diagnosis of NL by visualizing intense tracer uptake in affected neural structures, and it can support NL disease management (1,2,3,4,5,6,7). Most cases of NL have been diagnosed after disease progression or recurrence, but one research group noted that primary NL was described in about half of the reported NL cases (1,2,3).

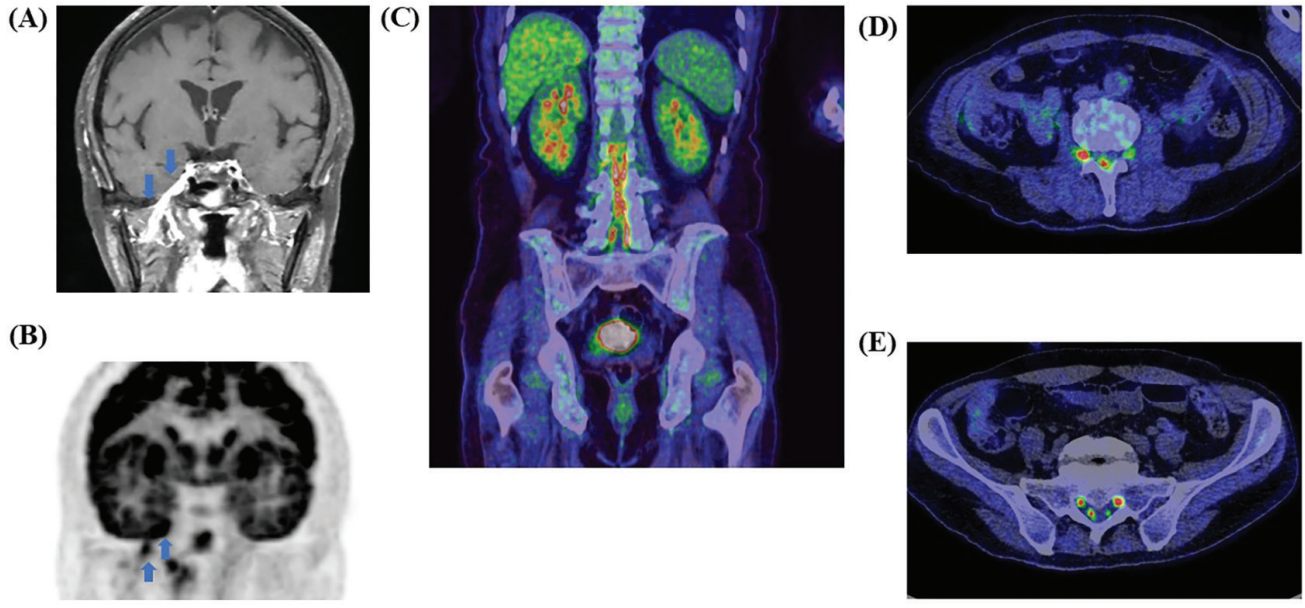

Figure 2. (A) Coronal contrast-enhanced T1-weighted MRI demonstrated fusiform/linear thickening and contrast enhancement of the right trigeminal nerve (arrows).
(B) Coronal PET image showed intense ^{18}F-FDG accumulation in the right trigeminal nerve [maximum standardized uptake value (SUV_{max})= 7.3] (arrows).
(C-E) Coronal and axial PET/CT fused images confirmed multiple intense ^{18}F-FDG-avid lesions in the lumbar and sacral plexuses (SUV_{max}= 10.4).
NL is categorized based on the presence of single or multiple lesions confirmed by imaging. The above-cited researchers showed that single-site involvement was more common (>70% of NL cases) than multiple-site involvement, which was reported in about half of the cases (1,2,3). Isolated neural involvement was the most common profile (48%), and cases with combined cranial, spinal, peripheral neural, and systemic extranodal involvement like the present patient are quite rare (7%) (1).
Overall survival was significantly better among patients with primary NL, and rituximab use in the frontline setting was associated with a significant improvement in progression-free survival among NL patients (1).

Ethics

Informed Consent: The patient provided written informed consent.

Footnotes

Authorship Contributions

Concept: K.K., K.Y., Design: K.K., K.H., K.Y., Data Collection or Processing: Y.M., K.K., K.H., Literature Search: Y.M., K.K., K.H., Writing: Y.M., K.K.

Conflict of Interest: No conflicts of interest were declared by the authors.

Financial Disclosure: The authors declare that this study has received no financial support.

References

1. Khurana A, Novo M, Nowakowski GS, Ristow KM, Spinner RJ, Hunt CH, King RL, Lachance DH, Habermann TM, Micallef IN, Johnston PB. Clinical manifestations of, diagnostic approach to, and treatment of neurolymphomatosis in the rituximab era. Blood Adv. 2021;5:1379-1387.
2. DeVries AH, Howe BM, Spinner RJ, Broski SM. B-cell peripheral neurolymphomatosis: MRI and ^{18}F-FDG PET/CT imaging characteristics. Skeletal Radiol. 2019;48:1043-1050.
3. Davidson T, Kedmi M, Avigdor A, Komisar O, Chikman B, Lidar M, Goshen E, Tzila Zwas S, Ben-Haim S. FDG PET-CT evaluation in neurolymphomatosis: imaging characteristics and clinical outcomes. Leuk Lymphoma. 2018;59:348-356.
4. Salm LP, Van der Hiel B, Stokkel MP. Increasing importance of ^{18}F-FDG PET in the diagnosis of neurolymphomatosis. Nucl Med Commun. 2012;33:907-16.
5. Salm LP, Van der Hiel B, Stokkel MP. Neurolymphomatosis diagnosed by (18)F-FDG PET-CT. Clin Nucl Med. 2013;38:e261-e262.
6. Gykiere P, Jans L, Degrieck B, Goethals I. Neurolymphomatosis on ^{18}F-FDG PET/CT: Diagnosis and therapy response. Clin Nucl Med. 2016;41:142-143.
7. Arçay A, Bural GG, Şenol U. Neurolymphomatosis with spinal nerve root involvement demonstrated on (18)F-FDG PET/CT. Mol Imaging Radionucl Ther. 2022;31:242-243.