Interesting Image

Mol Imaging Radionucl Ther **DOI:***10.4274/mirt.galenos.2026.61482*

Cervical ^{131}I Uptake Revealing an Occult Submandibular Sialolithiasis on SPECT/CT

SPECT/BT'de Okült Submandibular Sialolithiazisi Gösteren Servikal ^{131}I Tutulumu

Laila El Asraoui, Ayoub Dribla, Ayat Mouaden, Hasnae Guerrouj

National Institute of Oncology Sidi Mohamed Ben Abdellah, Clinic of Nuclear Medicine, Rabat, Morocco

Abstract

Radioiodine therapy iodine-131 (^{131}I) has been a cornerstone in the management of differentiated thyroid carcinoma. Although generally safe, it has been associated with salivary gland toxicity, including salivary çgland dysfunction and sialadenitis. We report a case of differentiated thyroid carcinoma in a patient who underwent post-therapy ^{131}I scintigraphy (3 mCi, 111 MBq) after levothyroxine withdrawal. During evaluation, sialolithiasis of the left submandibular duct was incidentally identified. Planar imaging showed focal, intense uptake in the left submandibular region; serum thyroglobulin was <0.1 ng/mL and anti-thyroglobulin antibodies were negative. Single photon emission computed tomography localized the uptake to a salivary duct stone, with upstream salivary stasis. The patient was asymptomatic.

Keywords: False-positive ^{131}I uptake, physiological uptake, sialolithiasis, SPECT/CT, differentiated thyroid carcinoma

Öz

Radyoiyot tedavisi iyot-131 (^{131}I), diferansiye tiroid karsinomunun yönetiminde temel bir yöntem olmuştur. Genellikle güvenli olmasına rağmen, disfonksiyon ve sialadenit dahil olmak üzere tükürük bezi toksisitesi ile ilişkilidir. Levotiroksin (3 mCi, 111 MBq) kesildikten sonra postterapi ^{131}I sintigrafisi yapılan diferansiye tiroid karsinomlu bir hastayı bildiriyoruz. Değerlendirme sırasında, tesadüfen sol submandibular kanal sialolithiazisi tespit edildi. Planar görüntüleme sol submandibular bölgede fokal yoğun tutulum gösterdi. Serum tiroglobulin düzeyi <0,1 ng/mL saptandı ve anti-tiroglobulin antikorları negatifti. Tek foton emisyon bilgisayarlı tomografisi/bilgisayarlı tomografi'deki tutulum, yukarı akışta tükürük stazına yol açan bir tükürük kanalı taşını lokalize etti. Hasta asemptomatikti.

Anahtar Kelimeler: Yanlış pozitif ^{131}I tutulumu, fizyolojik tutulum, sialolitiazis, SPECT/CT, diferansiye tiroid karsinomu

Address for Correspondence: Laila El Asraoui, National Institute of Oncology Sidi Mohamed Ben Abdellah, Clinic of Nuclear Medicine, Rabat, Morocco
E-mail: lailaa.elasraoui@gmail.com **ORCID ID:** orcid.org/0000-0003-4328-1853
Received: 05.06.2026 **Accepted:** 28.07.2026 **Epub:** 25.11.2026

Cite this article as: Asraoui LE, Dribla A, Mouaden A, Guerrouj H. Cervical ^{131}I uptake revealing an occult submandibular sialolithiasis on SPECT/CT. Mol Imaging Radionucl Ther. [Epub Ahead of Print]

Copyright© 2027 The Author(s). Published by Galenos Publishing House on behalf of the Turkish Society of Nuclear Medicine.
This is an open access article under the Creative Commons Attribution-NonCommercial-NoDerivatives 4.0 (CC BY-NC-ND) International License.

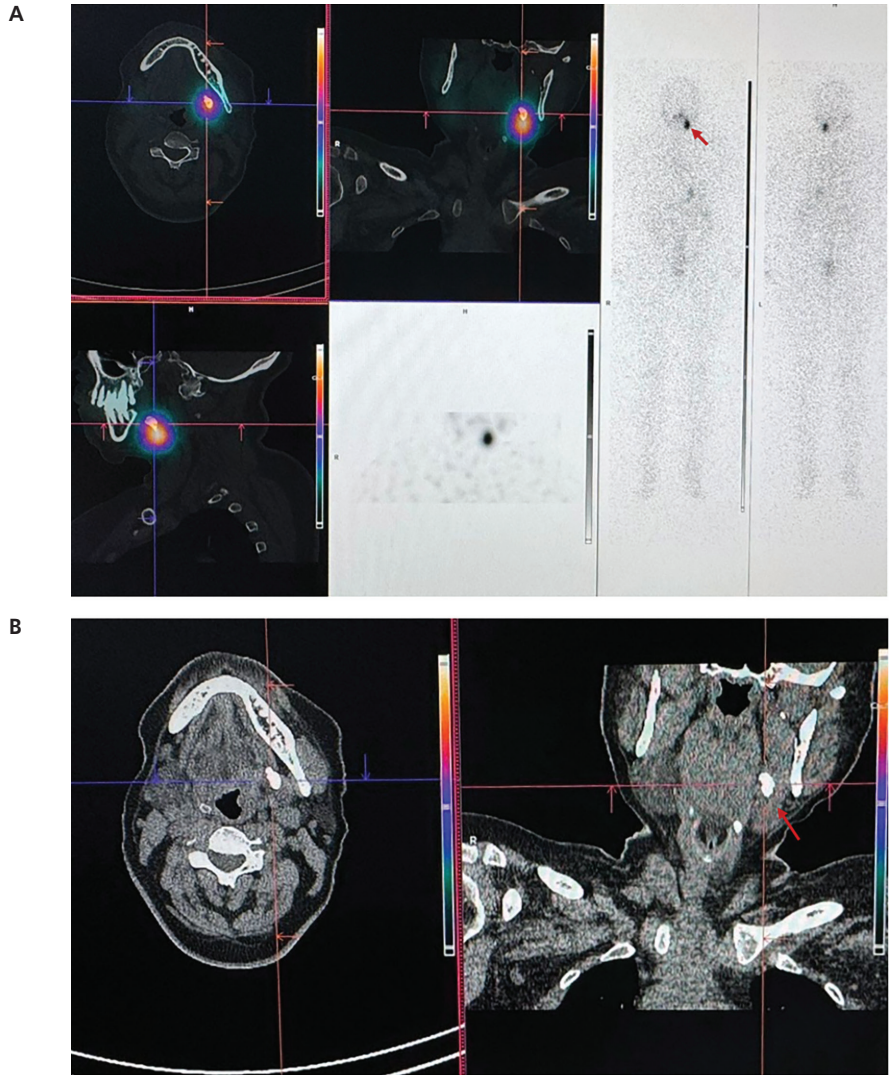

Figure 1. A whole-body iodine-131 (^{131}I) scan was performed 72 hours after oral administration of 3 mCi (111 MBq) of ^{131}I in a patient undergoing follow-up for differentiated thyroid carcinoma. Prior to imaging, levothyroxine therapy had been withdrawn for 3 weeks. At the time of imaging, serum thyroglobulin was <0.1 ng/mL and anti-thyroglobulin antibodies were <6.5 IU/mL.
Whole-body scintigraphy demonstrated an unexpectedly intense focal uptake in the left submandibular region (red arrow).
Given the negative anti-thyroglobulin antibodies and low thyroglobulin level, recurrent disease remained unlikely. Single photon emission computed tomography (SPECT/CT) of the neck was subsequently performed due to the intensity of radioiodine uptake and precisely localized the radioiodine accumulation to a left submandibular duct calculus (A,B), confirming salivary obstruction with upstream retention of iodine-rich saliva. The patient had no history of salivary gland swelling, pain, or symptoms suggestive of obstructive sialadenitis, making the finding entirely incidental.
Radioiodine (^{131}I) has been a cornerstone in the management of differentiated thyroid carcinoma. Although generally safe, it is associated with salivary gland toxicity, including dysfunction and sialadenitis (1).
Physiological radioiodine uptake is observed in salivary glands due to sodium-iodide symporter expression in ductal epithelial cells (2). As a result, benign salivary gland disorders may lead to abnormal I-131 retention on whole-body scintigraphy (2,3).
Among these conditions, sialolithiasis can cause ductal obstruction and impaired salivary clearance, resulting in focal tracer retention that may mimic cervical metastatic disease on planar imaging (4,5). In obstructive salivary gland disorders, SPECT/CT provides additional value by combining precise anatomical localization with functional assessment of salivary drainage, thereby improving diagnostic confidence in differentiating benign from malignant uptake (6). In the present case, SPECT/CT played a decisive role in accurately localizing the uptake and confirming its benign origin.
The absence of detectable thyroglobulin and negative anti-thyroglobulin antibodies strongly argued against persistent or recurrent differentiated thyroid carcinoma.
This case highlights the added value of hybrid imaging in resolving indeterminate or suspicious foci on ^{131}I scintigraphy and preventing misinterpretation during post-therapeutic surveillance.

Ethics

Informed Consent: The patient provided written informed consent for publication of this study and accompanying images.

Footnotes

Authorship Contributions

Concept: L.E.A., H.G., Design: L.E.A., A.D., H.G., Data Collection or Processing: L.E.A., A.D., H.G., Analysis or Interpretation: L.E.A., A.D., A.M., H.G., Literature Search: L.E.A., Writing: L.E.A.

Conflict of Interest: No conflicts of interest were declared by the authors.

Financial Disclosure: The authors declare that this study has received no financial support.

References

1. Haugen BR, Alexander EK, Bible KC, Doherty GM, Mandel SJ, Nikiforov YE, Pacini F, Randolph GW, Sawka AM, Schlumberger M, Schuff KG, Sherman SI, Sosa JA, Steward DL, Tuttle RM, Wartofsky L. 2015 American Thyroid Association management guidelines for adult patients with thyroid nodules and differentiated thyroid cancer: the American Thyroid Association Guidelines task force on thyroid nodules and differentiated thyroid cancer. Thyroid. 2016;26:1-133.
2. Bakheet SM, Powe J, Hammami MM. Radioiodine uptake in the chest. J Nucl Med. 1997;38:984-986.
3. Oh JR, Ahn BC. False-positive uptake on radioiodine whole-body scintigraphy: physiologic and pathologic variants unrelated to thyroid cancer. Am J Nucl Med Mol Imaging. 2012;2:362-385.
4. Rzymska-Grala I, Stopa Z, Grala B, Gołębiowski M, Wanyura H, Zuchowska A, Sawicka M, Zmorzyński M. Salivary gland calculi - contemporary methods of imaging. Pol J Radiol. 2010;75:25-37.
5. Wu K, Ozomaro U, Flavell R, Pampaloni M, Liu C. Causes of false-positive radioactive iodine uptake in patients with differentiated thyroid cancer. Curr Radiol Rep. 2021;9:6.
6. Tanabe Y, Ogura I. Submandibular sialolithiasis with CT and SPECT/CT: CT values, standardized uptake values, and salivary gland excretion in the parotid and submandibular glands. Dentomaxillofac Radiol. 2025;54:307-312.