Interesting Image

Mol Imaging Radionucl Ther **DOI:***10.4274/mirt.galenos.2026.59219*

Clarifying Equivocal ^{99m}Tc-Sestamibi Scintigraphy: ^{18}F-fluorocholine PET/CT and PET/MRI Co-Registration Unveil Parathyroid Adenoma and Skull Brown Tumor in Suspected MEN-1

Belirsiz ^{99m}Tc-Sestamibi Sintigrafisinin Aydınlatılması: MEN-1 Şüphesinde ^{18}F-florokolin PET/BT ve PET/MRG Füzyon Görüntüleme ile Paratiroid Adenomu ve Kafatası Brown Tümörünün Saptanması

Antonio Cairo[1]*, Angelo Spolidoro[2]*, Valentina Asta[2], Shyqyri Samarxhiu[2], Luca Filippi[1,2]

[1]*Catholic University "Our Lady of Good Counsel", Department of Biomedical Sciences, Tiranë, Albania*
[2]*University of Rome "Tor Vergata", Department of Biomedicine and Prevention, Rome, Italy*
**These authors contributed equally as first authors (listed in alphabetical order).*

Abstract

We report the case of a 50-year-old woman with a history of acromegaly who was evaluated for persistent hypercalcemia and elevated parathyroid hormone levels. Previous examinations, such as neck ultrasound and parathyroid scintigraphy with technetium-99m-sestamibi, were not conclusive for adenoma. ^{18}F-fluorocholine (^{18}F-CH) positron emission tomography (PET)/computed tomography showed focal pathological uptake in the retrothyroid region compatible with parathyroid adenoma and intense uptake at the level of the cranial vault in the occipital region. PET/magnetic resonance imaging co-registration also demonstrated ^{18}F-CH accumulation in the known pituitary microadenoma and in the occipital lesion. The bone lesion, initially considered an angioma, was reinterpreted as a brown tumor and was subsequently confirmed histologically. This case highlights the role of ^{18}F-CH PET in the localization of occult parathyroid adenomas and in the correct interpretation of bone lesions in a possible context of multiple endocrine neoplasia.

Keywords: ^{18}F-fluorocholine PET/CT, hyperparathyroidism, brown tumor, MEN1, PET/MRI co-registration

Öz

Bu yazıda, akromegali öyküsü olan ve persistan hiperkalsemi ile yüksek paratiroid hormonu düzeyleri nedeniyle değerlendirilen 50 yaşındaki bir kadın hastayı sunuyoruz. Boyun ultrasonu ve teknesyum-99m-sestamibi ile yapılan paratiroid sintigrafisi gibi daha önceki incelemeler, adenom açısından kesin bir bulgu ortaya koymamıştı. Flor-18 ile işaretlenmiş florokolin (^{18}F-CH) pozitron emisyon tomografisi (PET)/bilgisayarlı tomografi incelemesinde, retrotiroid bölgede paratiroid adenomu ile uyumlu fokal patolojik tutulum ve oksipital bölgedeki kraniyal kubbe düzeyinde yoğun tutulum izlendi. PET/manyetik rezonans görüntüleme füzyon görüntülemede ise, bilinen hipofiz mikroadenomunda ve oksipital lezyonda ^{18}F-CH birikimi saptandı. Başlangıçta anjiyom olduğu düşünülen kemik lezyonu, brown tümörü olarak yeniden değerlendirildi ve daha sonra histolojik olarak

Address for Correspondence: Luca Filippi, MD, University of Rome "Tor Vergata", Department of Biomedicine and Prevention, Rome, Italy
E-mail: luca.filippi@uniroma2.it **ORCID ID:** orcid.org/0000-0003-4423-5496
Received: 08.09.2026 **Accepted:** 09.11.2026 **Epub:** 25.11.2026

Cite this article as: Cairo A, Spolidoro A, Asta V, Samarxhiu S, Filippi L. Clarifying equivocal ^{99m}Tc-sestamibi scintigraphy: ^{18}F-fluorocholine PET/CT and PET/MRI co-registration unveil parathyroid adenoma and skull brown tumor in suspected MEN-1. Mol Imaging Radionucl Ther. [Epub Ahead of Print]

Copyright© 2026 The Author(s). Published by Galenos Publishing House on behalf of the Turkish Society of Nuclear Medicine.
This is an open access article under the Creative Commons Attribution-NonCommercial-NoDerivatives 4.0 (CC BY-NC-ND) International License.

doğrulandı. Bu olgu, multipl endokrin neoplazi şüphesi olan durumlarda, gizli paratiroid adenomlarının lokalizasyonunda ve kemik lezyonlarının doğru yorumlanmasında ^{18}F-CH PET'in rolünü vurgulamaktadır.

Anahtar Kelimeler: ^{18}F-florokolin PET/BT, hiperparatiroidizm, Brown tümörü, MEN1, PET/MRG füzyon görüntüleme

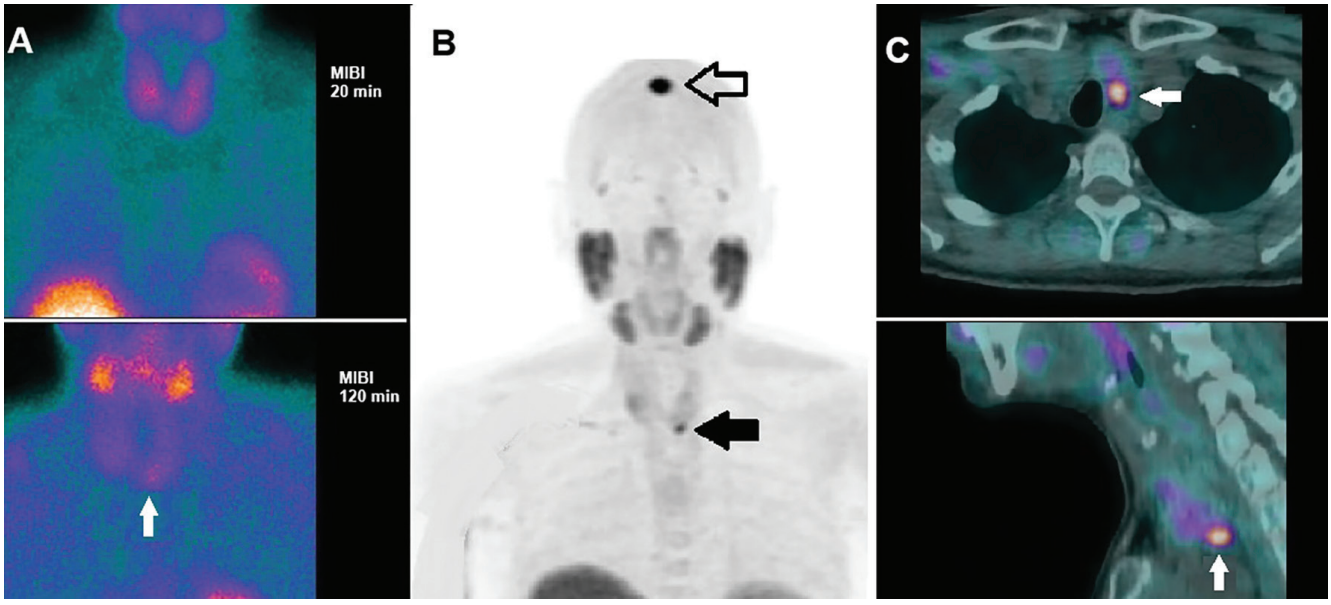

Figure 1. A 50-year-old woman with a history of acromegaly diagnosed at age 34, secondary to a growth hormone-secreting pituitary microadenoma, was referred for evaluation of persistent hypercalcemia (11.2 mg/dL) and elevated parathyroid hormone levels (186 pg/mL). Her acromegaly had been medically managed with somatostatin analogs (octreotide long-acting release, later switched to lanreotide autogel), resulting in good overall biochemical control. She reported a recent-onset occipital headache. Contrast-enhanced brain magnetic resonance imaging confirmed the known 6 mm pituitary microadenoma and revealed an approximately 20 mm occipital lesion, which was initially suggestive of a low-flow vascular malformation. Initial diagnostic workup, including neck ultrasound and technetium-99m (^{99m}Tc)-sestamibi parathyroid scintigraphy, yielded equivocal/inconclusive findings. Due to persistent primary hyperparathyroidism and inconclusive conventional imaging, she underwent ^{18}F-fluorocholine (^{18}F-CH) positron emission tomography/computed tomography (PET/CT). (A) Parathyroid scintigraphy, performed using a dual-phase ^{99m}Tc-sestamibi protocol acquiring planar images at 20 min (early, upper row), 60 min (not shown), and 120 min (delayed, lower row), demonstrated only faint uptake inferior to the left thyroid lobe. Thyroid subtraction imaging was omitted due to concurrent levothyroxine therapy (75 mcg/day). Planar images were acquired using a parallel-hole collimator in accordance with the imaging protocol available at our institution at the time of the examination (neither pinhole imaging nor single-photon emission computed tomography (SPECT) acquisitions were performed; SPECT/CT was not available at our center). (B) ^{18}F-CH maximum intensity projection showed intense focal uptake at the level of the cranial vault in the occipital region (white arrow) and another hypermetabolic area in the lower cervical region (black arrow). (C) Fused axial PET/CT (upper row) showed focal pathological uptake in the left retrothyroid region, posterior to the thyroid lobe, compatible with a parathyroid adenoma [white arrow; size: ~12 mm; maximum standardized uptake value (SUV_{max}) 9.4]. Fused sagittal PET/CT (lower row) confirmed the localization of the hypermetabolic lesion in the left retrothyroid region (white arrow).

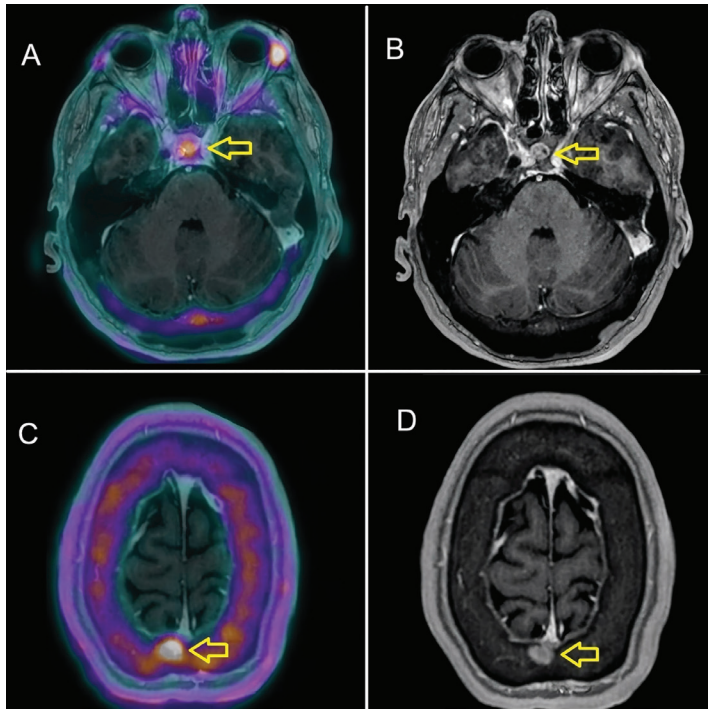

Figure 2. (A) Multimodal image fusion through co-registration of contrast-enhanced T1-weighted magnetic resonance imaging (MRI) images and ^{18}F-CH PET (advantage GE v4.7, GE healthcare) demonstrated focal radiotracer uptake (SUV_{max} 6.7) corresponding to the known pituitary microadenoma (yellow arrow), clearly identified on the contrast-enhanced T1-weighted images (B). (C) Fused PET/MRI demonstrated focal and intense radiotracer uptake (SUV_{max} 16.2), allowing more accurate characterization of the occipital lesion. (D) T1-weighted images showed a ~20-mm occipital lesion, initially interpreted as a possible angioma. The increased tracer uptake, interpreted in conjunction with the clinical and biochemical evidence of primary hyperparathyroidism, raised suspicion of a brown tumor rather than the initially proposed vascular lesion. The diagnosis was subsequently confirmed by histopathological examination.

In recent years, ^{18}F-CH PET/CT, initially developed for prostate cancer imaging (1), has seen a decline in that setting with the advent of prostate-specific membrane antigen-targeted radiotracers, which offer superior diagnostic performance (2). However, it has gained increasing relevance in the evaluation of hyperparathyroidism, where it demonstrated high sensitivity in detecting hyperfunctioning parathyroid tissue, particularly in cases with negative conventional imaging (3). In this context, ^{18}F-CH PET, in addition to the visualization of parathyroid adenomas, allows identification of additional foci characterized by increased phospholipid membrane synthesis within the acquisition field of view, which are often reported in the literature as incidentalomas (4). While ^{18}F-CH uptake in pituitary adenomas has been described during PET performed for prostate neoplasms, the detection of brown tumors is extremely rare (5). Our case highlights the pivotal role of ^{18}F-CH PET/CT in the evaluation of a complex endocrine setting in the presence of negative or inconclusive conventional imaging. Despite parathyroid scintigraphy with ^{99m}Tc-sestamibi and neck ultrasound not having identified focal lesions, PET/CT allowed the simultaneous identification of three well-distinct pathological lesions. It should be acknowledged that the initial scintigraphic assessment was limited to conventional planar imaging with a parallel-hole collimator, reflecting the diagnostic resources available at our institution at the time of examination. Pinhole imaging and SPECT, particularly when combined with CT, may improve the detection and localization of small parathyroid lesions (6,7). Nevertheless, pinhole imaging also has inherent limitations related to its restricted field of view and geometric distortion. This case therefore illustrates the incremental value of ^{18}F-CH PET/CT in a real-world diagnostic setting rather than establishing its superiority over optimized scintigraphic protocols.

The identified lesions were clinically relevant because they were associated with significant symptomatic and functional impact on the patient. The occipital lesion had initially been interpreted on contrast-enhanced MRI as a possible low-flow vascular malformation. Although assessment of the CT component of PET/CT using bone-window settings may provide additional morphological information, the integration of ^{18}F-CH PET with MRI enabled direct correlation between metabolic activity and the previously identified anatomical abnormality. In the clinical context of primary hyperparathyroidism, this finding raised suspicion of a brown tumor, which was subsequently confirmed by histopathological examination. Beyond anatomical localization, PET/MRI co-registration provided complementary functional and morphological information, facilitating the characterization of the occipital lesion in the context of primary hyperparathyroidism. Although this multimodal approach may potentially support biopsy planning in selected cases, its specific contribution to biopsy targeting cannot be established from the present case (8). In our patient, the association between acromegaly and hyperparathyroidism raised suspicion of multiple endocrine neoplasia type 1 (9), although still not genetically confirmed, making genetic evaluation and endocrinological follow-up necessary. In conclusion, this case demonstrates how ^{18}F-CH PET/CT can provide a comprehensive evaluation with high clinical impact, allowing the simultaneous identification of multiple lesions and decisively guiding the diagnostic and therapeutic pathway.

Ethics

Informed Consent: The authors certify that they have obtained all appropriate patient consent forms. On the form, the patient has given consent for their images and other clinical information to be reported in the journal. The patient understands that the patient's name and initials will not be published, and every effort will be made to conceal their identity, but anonymity cannot be guaranteed.

Footnotes

Authorship Contributions

Concept - Design - Analysis or Interpretation - Writing: All authors contributed equally to this study.

Conflict of Interest: No conflict of interest was declared by the authors.

Financial Disclosure: The authors declared that this study received no financial support.

References

1. Kim DY, Lee WW, Song YS, Hong SK, Byun SS, Kim JS. Detection of recurrence sites using ^{18}F-fluorocholine PET/CT in prostate cancer patients with PSA failure. Prostate Int. 2023;11:69-75.
2. Shen Z, Li Z, Li Y, Tang X, Lu J, Chen L, Cheng ZZ, Liao H, Zhou S. PSMA PET/CT for prostate cancer diagnosis: current applications and future directions. J Cancer Res Clin Oncol. 2025;151:155.
3. Filippi L, Bianconi F, Ferrari C, Linguanti F, Battisti C, Urbano N, Minestrini M, Messina SG, Buci L, Baldoncini A, Rubini G, Schillaci O, Palumbo B. Digital versus analogue PET in parathyroid imaging: comparison of PET metrics and machine learning-based characterisation of hyperfunctioning lesions (the DIGI-PET study). Eur J Nucl Med Mol Imaging. 2026;53:2122-2130.
4. Hodolic M, Huchet V, Balogova S, Michaud L, Kerrou K, Nataf V, Cimitan M, Fettich J, Talbot JN. Incidental uptake of (18)F-fluorocholine (FCH) in the head or in the neck of patients with prostate cancer. Radiol Oncol. 2014;48:228-234.
5. Rogic I, Huic D. Detection of brown tumors by [^{18}F]F-choline PET/CT performed in a patient with secondary hyperparathyroidism. Nucl Med Rev Cent East Eur. 2023;26:49-51.
6. Tomas MB, Pugliese PV, Tronco GG, Love C, Palestro CJ, Nichols KJ. Pinhole versus parallel-hole collimators for parathyroid imaging: an intraindividual comparison. J Nucl Med Technol. 2008;36:189-194.
7. Carlier T, Oudoux A, Mirallié E, Seret A, Daumy I, Leux C, Bodet-Milin C, Kraeber-Bodéré F, Ansquer C. ^{99m}Tc-MIBI pinhole SPECT in primary hyperparathyroidism: comparison with conventional SPECT, planar scintigraphy and ultrasonography. Eur J Nucl Med Mol Imaging. 2008;35:637-643.
8. Jena A, Taneja S, Jha A. Simultaneous PET/MRI: Impact on cancer management-A comprehensive review of cases. Indian J Radiol Imaging. 2014;24:107-116.
9. Delemer B. MEN1 and pituitary adenomas. Ann Endocrinol (Paris). 2012;73:59-61.