Interesting Image

Mol Imaging Radionucl Ther **DOI:***10.4274/mirt.galenos.2026.03271*

Desquamative Interstitial Pneumonia: A Rare Diagnostic Pitfall Mimicking Lung Metastases in Differentiated Thyroid Cancer

Diferansiye Tiroid Kanserinde Akciğer Metastazlarını Taklit Eden Nadir Bir Tanı Tuzağı: Deskuamatif İnterstisyel Pnömoni

Fatih Tamer[1], Akın Çinkooğlu[2], Ayşegül Akgün[1]

[1]*Ege University Faculty of Medicine, Department of Nuclear Medicine, İzmir, Türkiye*
[2]*Ege University Faculty of Medicine, Department of Radiology, İzmir, Türkiye*

Abstract

A 50-year-old woman with papillary thyroid cancer received 150 mCi of radioactive iodine therapy (RAIT) in 2022. Post-treatment whole-body scintigraphy showed diffuse pulmonary uptake interpreted as miliary metastasis. In 2025, a second RAIT dose was followed by new focal lung uptake despite declining thyroglobulin levels. By integrating descriptive computed tomography (CT) findings with the clinical history (smoking and ankylosing spondylitis), the radiologist identified desquamative interstitial pneumonia (DIP) on high-resolution CT. Consequently, the lung findings were interpreted as false-positive uptake. This case highlights DIP as a previously unreported etiology of false-positive iodine-131 uptake, emphasizing that the meticulous integration of clinical, laboratory, and imaging data is crucial for preventing misdiagnosis in differentiated thyroid cancer management.

Keywords: Desquamative interstitial pneumonia, differantiated thyroid cancer, radioactive iodine

Öz

Papiller tiroid kanserli 50 yaşında bir kadın hasta, 2022 yılında 150 mCi radyoaktif iyot tedavisi (RAIT) aldı. Tedavi sonrası tüm vücut sintigrafisinde (WBS) miliyer metastaz olarak yorumlanan yaygın pulmoner tutulum görüldü. 2025 yılında uygulanan ikinci bir RAIT dozu, gerileyen tiroglobulin seviyelerine rağmen yeni gelişen fokal akciğer tutulumunu saptadı. Tanımlayıcı bilgisayarlı tomografi (BT) bulguları ve klinik öykü (sigara kullanımı ve ankilozan spondilit) birlikte değerlendirildiğinde, yüksek çözünürlüklü BT ile deskuamatif interstisyel pnömoni (DİP) tanısı konuldu. Sonuç olarak, akciğer bulguları yalancı pozitif tutulum olarak yeniden yorumlandı. Bu olgu, DİP'i daha önce bildirilmemiş bir yalancı pozitif iyot-131 tutulum etiyolojisi olarak vurgulamakta ve diferansiye tiroid kanseri yönetiminde yanlış tanıların önlenmesi için klinik, laboratuvar ve görüntüleme verilerinin titizlikle bütünleştirilmesinin önemini vurgulamaktadır.

Anahtar Kelimeler: Deskuamatif interstisyel pnömoni, diferansiye tiroid kanseri, radyoaktif iyot

Address for Correspondence: Fatih Tamer, MD, Ege University Faculty of Medicine, Department of Nuclear Medicine, İzmir, Türkiye
E-mail: drfatihtamer@gmail.com **ORCID ID:** orcid.org/0000-0002-5656-9955
Received: 16.09.2026 **Accepted:** 16.11.2026 **Epub:** 25.11.2026

Cite this article as: Tamer F, Çinkooğlu A, Akgün A. Desquamative interstitial pneumonia: a rare diagnostic pitfall mimicking lung metastases in differentiated thyroid cancer. Mol Imaging Radionucl Ther. [Epub Ahead of Print]

Copyright© 2026 The Author(s). Published by Galenos Publishing House on behalf of the Turkish Society of Nuclear Medicine.
This is an open access article under the Creative Commons Attribution-NonCommercial-NoDerivatives 4.0 (CC BY-NC-ND) International License.

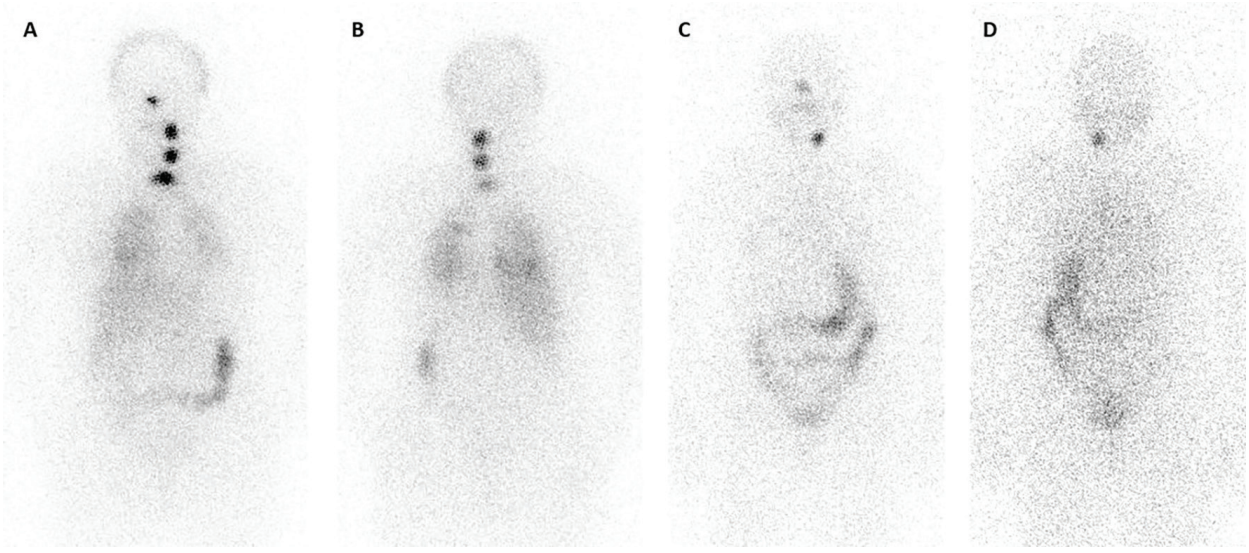

Figure 1. A 50-year-old woman underwent total thyroidectomy in 2022 for unilobar multifocal papillary thyroid cancer of the left lobe (largest tumor size 1.5 cm; classical subtype; T1b). Left central and lateral lymph node (LN) dissection revealed metastases in 9 of 29 nodes (N1b; largest 4 cm). Post-operative neck ultrasound (US) revealed residual tissue in the thyroidectomy bed and no pathological LNs in the left cervical chain; chest computed tomography (CT) was negative for metastasis. In April 2022, the patient received 150 mCi of radioactive iodine therapy (RAIT) [stimulated thyroglobulin (Tg) 37.7 ng/mL, anti-Tg <15 IU/mL]. Post-treatment whole-body scan (PT-WBS) demonstrated residual uptake in the thyroidectomy bed and left upper cervical region along with diffuse, mildly increased pulmonary uptake, the latter interpreted as miliary metastases that were not detected on non-thin-section staging CT (A, B). Follow-up neck US and magnetic resonance imaging remained negative for pathological nodes. Diagnostic WBS (5 mCi) in May 2023 showed a marked Tg decline (stimulated Tg of 4 ng/mL; anti-Tg <15 IU/mL), indicating regression of prior pulmonary and cervical findings (C, D).

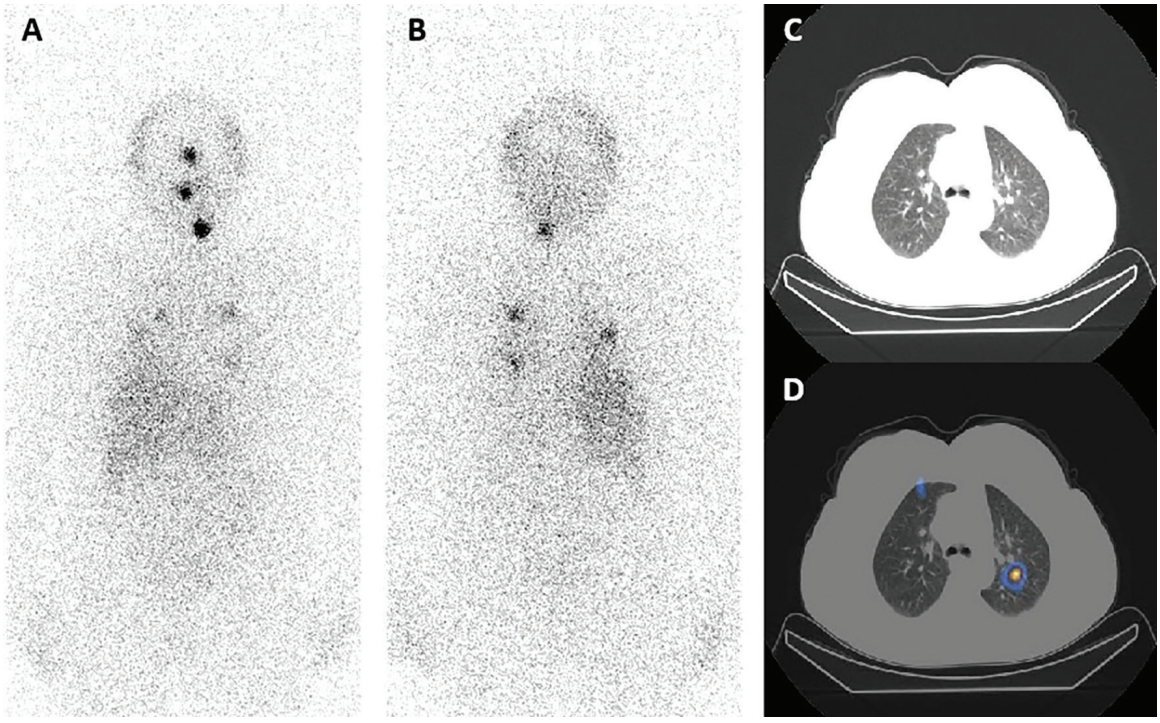

Figure 2. Despite a decline in suppressed Tg (from 2.46 to 0.12 ng/mL), a second RAIT dose (150 mCi) was administered in March 2025 (stimulated Tg 2.79 ng/mL, anti-Tg <15 IU/mL) because of the lower sensitivity of low-dose (5 mCi) scans compared with therapeutic high-dose scans and to achieve an excellent response (negative imaging, stimulated Tg <1 ng/mL). PT-WBS planar images (A, B) and single-photon emission CT (SPECT)/CT showed partial resolution of residual uptake; however, new focal uptake appeared in both lungs, contrasting with the previously diffuse pattern. Cranial focal uptake was attributed to physiological nasal/oral activity.

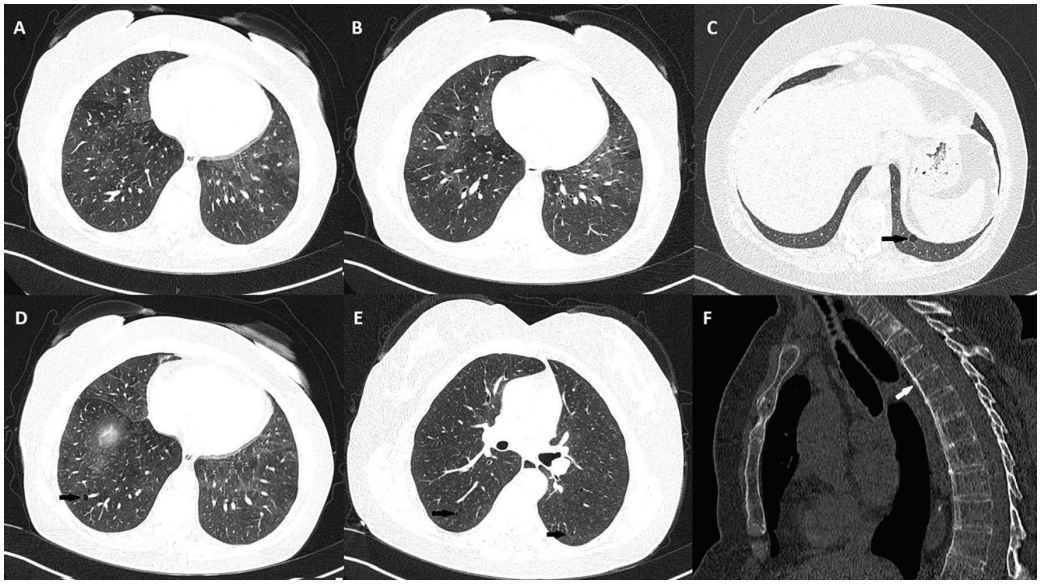

Figure 3. Due to clinical-laboratory discordance (decline in stimulated Tg and alterations in the [iodine-131 (^{131}I) uptake], a thin-section post-second-treatment high-resolution CT (HRCT) scan revealed a mosaic attenuation (A, B), ground-glass opacities (A, B), and millimeter-sized air cysts (C, D, E, black arrows). Although direct comparison between low-dose SPECT/CT and HRCT images remains limited, the absence of corresponding metastatic nodules on SPECT/CT, together with characteristic radiological features, suggested false-positive uptake and led to a presumptive diagnosis of desquamative interstitial pneumonia (DIP) (recently termed alveolar macrophage pneumonia). Thoracic ankylosis and increased kyphosis were also noted (F, white arrow). A detailed review of the patient's medical history revealed that they was a smoker and had a 10-year history of ankylosing spondylitis, for which they were receiving secukinumab treatment. DIP is primarily linked to smoking, inhalational exposures, and autoimmune conditions. Pathologically characterized by intra-alveolar accumulation of macrophages and fibrosis, DIP typically presents on imaging with bilateral lower-lobe ground-glass opacities, which may progress to cysts and traction bronchiectasis. While false-positive ^{131}I uptake occurs in conditions like bronchiectasis, tuberculosis, and fungal infections, this case highlights DIP as a previously unreported rare etiology (1,2,3,4,5,6,7,8). Diagnostic WBS in Feb 2026 was normal (stimulated Tg 0.37 ng/mL; anti-Tg 22.4 IU/mL), indicating an excellent response to TSH suppression. This report highlights the importance of integrating clinical, laboratory, and imaging data in differentiated thyroid cancer management. Furthermore, meticulous interpretation of pulmonary uptake of ^{131}I is crucial to avoid misdiagnosis and overtreatment of rare, specific pulmonary diseases such as DIP.

Ethics

Informed Consent: Written informed consent was obtained from the patient before imaging and therapies.

Footnotes

Authorship Contributions

Surgical and Medical Practices: F.T., A.Ç., A.A., Concept: F.T., A.Ç., A.A., Design: F.T., A.Ç., A.A., Data Collection or Processing: F.T., Analysis or Interpretation: F.T., A.A., Literature Search: F.T., Writing: F.T.

Conflict of Interest: No conflict of interest was declared by the authors.

Financial Disclosure: The authors declared that this study received no financial support.

References

1. Bakheet SM, Hammami MM, Powe J. Radioiodine uptake in rheumatoid arthritis-associated lung disease mimicking thyroid cancer metastases. Clin Nucl Med. 1998;23:319-320.
2. Ahn BC, Lee SW, Lee J, Kim C. Pulmonary aspergilloma mimicking metastasis from papillary thyroid cancer. Thyroid. 2011;21:555-558.
3. Triggiani V, Moschetta M, Giagulli VA, Licchelli B, Guastamacchia E. Diffuse ^{131}I lung uptake in bronchiectasis: a potential pitfall in the follow-up of differentiated thyroid carcinoma. Thyroid. 2012;22:1287-1290.
4. Jiménez-Bonilla JF, Bravo Z, Quirce R, Martínez-Rodríguez I, Banzo I, Gómez J, Del Castillo-Matos R, Ortega-Nava F, Amado JA, Carril JM. An exceptional false-positive finding in the postsurgical I 131 whole body scan of a differentiated thyroid carcinoma caused by an extralobar pulmonary sequestration. J Clin Endocrinol Metab. 2013;98:1797-1798.
5. Thientunyakit T. False-positive ^{131}I whole-body scan in well-differentiated thyroid cancer patient with respiratory bronchiolitis. Clin Nucl Med. 2013;38:730-734.
6. Jia C, Moadel R, Freeman LM. Focal thoracic uptake mimicking lung metastasis on ^{131}I post-therapy whole-body scan in patients with thyroid carcinoma. Clin Nucl Med. 2014;39:360-362.
7. Spinapolice EG, Chytiris S, Fuccio C, Leporati P, Volpato G, Villani L, Trifirò G, Chiovato L. Pulmonary sequestration: a (131)I whole body scintigraphy false-positive result. Ann Nucl Med. 2014;28:683-687.
8. Posocco D, Kamat B, Dadparvar S. False-positive 123I-uptake mimics metastatic lung disease in a patient with interstitial lung disease secondary to scleroderma. Clin Nucl Med. 2022;47:79-80.