Interesting Image

Mol Imaging Radionucl Ther **DOI:***10.4274/mirt.galenos.2026.02418*

Beyond The Skeletal Frame: Bone Scan Revealing Hidden Rectovesical Fistula

İskelet Sisteminin Ötesinde: Gizli Rektovezikal Fistülü Ortaya Koyan Kemik Sintigrafisi

Muntaha Fatima Rana[1], Fatima Yousaf[1], Mairah Razi[1], Sana Akhtar[2], Aamna Hassan[1]

[1]*Shaukat Khanum Memorial Cancer Hospital and Research Centre, Clinic of Nuclear Medicine, Lahore, Pakistan*
[2]*Shaukat Khanum Memorial Cancer Hospital and Research Centre, Clinic of Radiology, Lahore, Pakistan*

Abstract

Tc-99m methylene diphosphonate (^{99m}Tc MDP) bone scan is an effective tool for evaluating benign and malignant skeletal disorders. Radiotracer uptake in the bowel on bone scan is an uncommon finding and may represent an important non-osseous abnormality. We present the image of a patient with intermediate-risk prostate cancer who underwent a bone scan for metastatic workup, which revealed diffuse abnormal uptake in the left side of the pelvis and lumbar region. Correlation with single photon emission computed tomography/computed tomography (SPECT/CT) localized this uptake to the rectosigmoid colon, raising suspicion of a recto-vesical fistula that was later confirmed on magnetic resonance imaging (MRI) of the pelvis. The case highlights the importance of recognizing unexpected extraosseous tracer distribution and of carefully reviewing the SPECT/CT, which may reveal clinically relevant abnormalities and influence patient management.

Keywords: Rectovesical, fistula, bone scan

Öz

^{99m}Tc-metoksiizobütilizonitri (^{99m}Tc MDP) kemik sintigrafisi, benign ve malign iskelet sistemi hastalıklarının değerlendirilmesinde etkili bir yöntemdir. Kemik sintigrafisinde bağırsaklarda radyotraser tutulumu görülmesi nadir bir bulgudur ve önemli, kemik dışı bir anormalliğe işaret edebilir. Bu yazıda, metastaz taraması amacıyla kemik sintigrafisi çekilen ve pelvik bölgenin sol tarafı ile lomber bölgede yaygın anormal tutulum saptanan, orta riskli prostat kanserli bir hastanın görüntüleri sunulmaktadır. Tek foton emisyon bilgisayarlı tomografi/bilgisayarlı tomografi (SPECT/CT) incelemesinde bu tutulumun rektosigmoid kolona lokalize olduğu görülmüş ve rektovezikal fistül şüphesi doğmuştur; bu şüphe daha sonra pelvik manyetik rezonans görüntüleme (MRG) ile doğrulanmıştır. Bu olgu, beklenmedik kemik dışı izleyici dağılımını fark etmenin ve klinik açıdan önemli anormallikleri ortaya çıkarıp hasta yönetimini etkileyebilecek SPECT/CT görüntülerini dikkatle incelemenin önemini vurgulamaktadır.

Anahtar Kelimeler: Rektovezikal, fistül, kemik sintigrafisi

Address for Correspondence: Muntaha Fatima Rana, Shaukat Khanum Memorial Cancer Hospital and Research Centre, Clinic of Nuclear Medicine, Lahore, Pakistan
E-mail: muntahafatima@skm.org.pk **ORCID ID:** orcid.org/0009-0009-9720-5515
Received: 18.05.2026 **Accepted:** 21.09.2026 **Epub:** 25.11.2026

Cite this article as: Rana MF, Yousaf F, Razi M, Akhtar S, Hassan A. Beyond the skeletal frame: bone scan revealing hidden rectovesical fistula. Mol Imaging Radionucl Ther. [Epub Ahead of Print]

Copyright© 2026 The Author(s). Published by Galenos Publishing House on behalf of the Turkish Society of Nuclear Medicine.
This is an open access article under the Creative Commons Attribution-NonCommercial-NoDerivatives 4.0 (CC BY-NC-ND) International License.

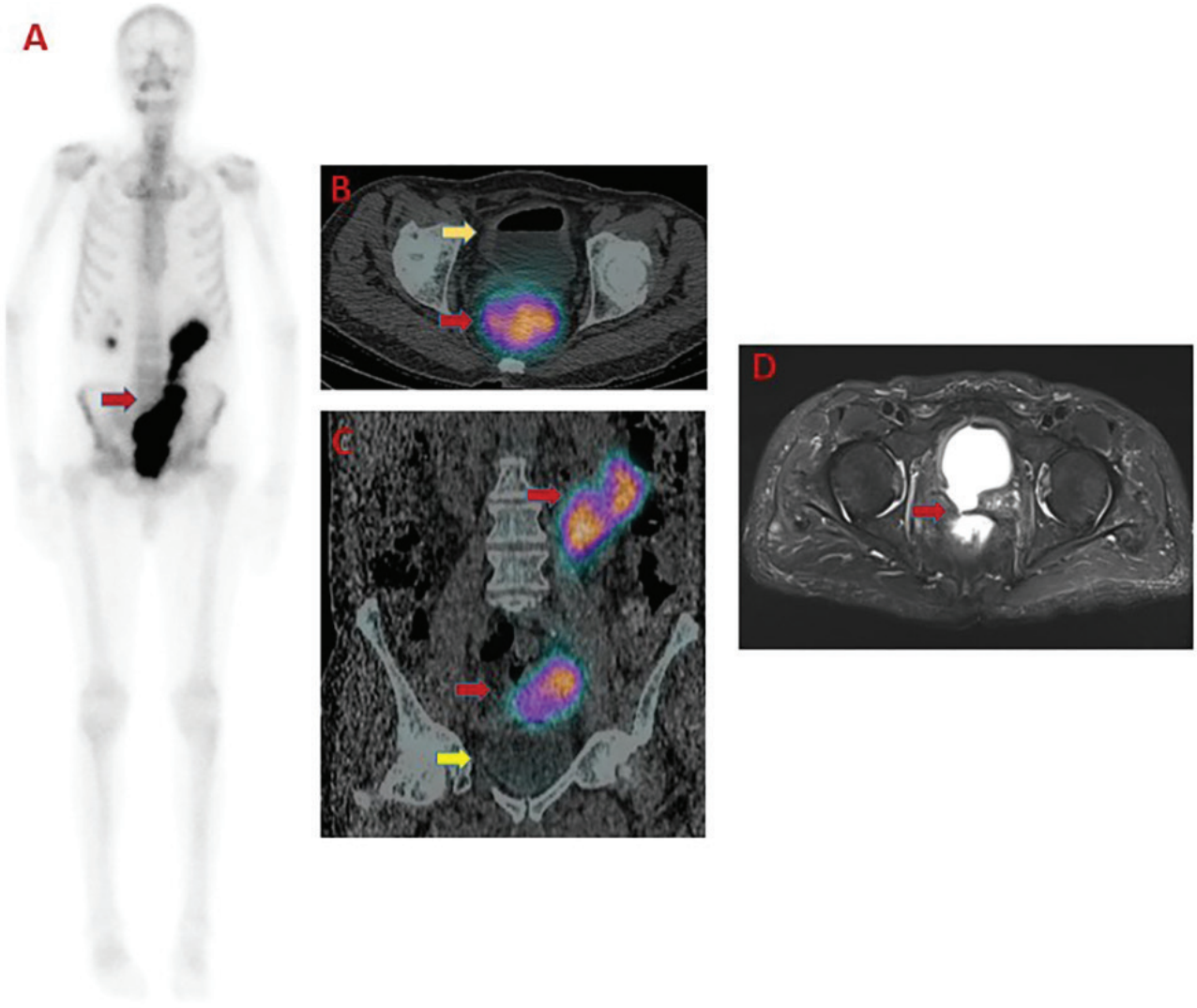

Figure 1. A 63-year-old man with prostate adenocarcinoma was referred to the nuclear medicine department for a bone scan as part of his baseline metastatic workup. He underwent transurethral resection of the prostate (TURP) 6 weeks earlier, and hormonal therapy was initiated. Whole-body bone scan (A: Planar image) showed no evidence of osteoblastic skeletal metastases; however, intense uptake in the left lumbar region extending into the pelvis was demonstrated (red arrow). Single photon emission computed tomography/computed tomography (SPECT/CT) images (B: fused axial, C: fused coronal) revealed uptake in the rectosigmoid colon (red arrows) and showed no tracer uptake in the bladder (yellow arrows). CT scan and abdominal magnetic resonance imaging (MRI) were unremarkable for metastases. Clinically, the patient has had multiple emergency room visits for loose stools since TURP. Based on the bone scan findings, a suspicion of rectovesical fistula was raised, and MRI pelvis (D) was reviewed, confirming the rectovesical fistula (red arrow).

Rectovesical fistula is defined as an abnormal connection between rectum and bladder commonly occurring secondary to inflammation, tumor, trauma from recent surgical intervention, congenitally or as a result of chemo- or radiotherapy (1,2,3). They are also reported after prostate related procedures (4). Common presentations include severe urinary tract infection, fecaluria, pneumaturia and urine leak through anus (5). Colon can be incidentally seen on bone scan due to fistulous communication between bowel and bladder (6,7). Intestinal uptake on bone scan can occur due to various causes like gastrointestinal bleed, tumor, enterocolitis, infarction, and protein losing enteropathy (8). Therefore, unexpected radiotracer uptake in the bowel on a bone scan should prompt careful evaluation and correlation with available anatomical imaging and clinical history. This case emphasizes the importance of unusual extra-osseous uptake on bone scan, which can reveal an important incidental finding; in our case, it was a missed rectovesical fistula.

Ethics

Informed Consent: Waiver of informed consent was obtained from Institution review board as this is a retrospective review with information gathered in such a way that patient's identity will be confidential and information gathered only from physician's notes and reports (IRB number: EX-02-06-25-03).

Footnotes

Authorship Contributions

Concept: M.F.R., M.R., A.H., Design: M.F.R., M.R., A.H., Data Collection or Processing: M.F.R., S.A., Analysis or Interpretation: M.R., S.A., A.H., Literature Search: M.F.R., Writing: M.F.R., F.Y., M.R., A.H.

Conflict of Interest: No conflicts of interest were declared by the authors.

Financial Disclosure: The authors declare that this study has received no financial support.

References

1. Chiang SF, Hung HY, Changchien CR, Chen JS, Tang R. Is surgical intervention always needed for traumatic rectovesical fistula? We demonstrate an experience of nonsurgical management of traumatic rectovesical fistula. Injury Extra. 2009;40:29-31.
2. Yang CH, Liu KH, Chen TC, Chang PL, Yeh TS. Enterovesical fistula caused by a bladder squamous cell carcinoma. World J Gastroenterol. 2009;15:4215-4217.
3. Nunoo-Mensah JW, Kaiser AM, Wasserberg N, Saedi H, Quek ML, Beart RW. Management of acquired rectourinary fistulas: how often and when is permanent fecal or urinary diversion necessary? Dis Colon Rectum. 2008;51:1049-1054.
4. Sotelo R, Mirandolino M, Trujillo G, Garcia A, de Andrade R, Carmona O, Sánchez L, Rodriquez E, Finelli A. Laparoscopic repair of rectourethral fistulas after prostate surgery. Urology. 2007;70:515-518.
5. Sotelo R, de Andrade R, Carmona O, Astigueta J, Velasquez A, Trujillo G, Canes D. Robotic repair of rectovesical fistula resulting from open radical prostatectomy. Urology. 2008;72:1344-1346.
6. Balan KK, Critchley M. Vesico-colic fistula. An unexpected finding on Tc-99m MDP bone imaging. Clin Nucl Med. 1997;22:192-193.
7. Kim SH, Song BI, Won KS. Colon visualization on ^{99m}Tc-HDP whole-body bone scan due to sigmoid colon cancer–related enterovesical fistula. Clin Nucl Med. 2015;40:68-69.
8. Eftekhari M, Fard-Esfahani A, Haghighatafshar M, Keivan A, Beiki D, Aghahosseini F, Emami-Ardekani A, Saghari M. Bone scan with incidental visualization of the entire colon. Iran J Nucl Med. 2010;18:56-59.